

EFSUMB



EFSUMB – European Course Book

Editor: Christoph F. Dietrich

Ultrasound of the scrotum

Paul S. Sidhu, Boris Brkljacic², Lorenzo E. Derchi³

²Medical School, University of Zagreb, ³Department of Radiology, University of Genoa

Corresponding author:

Paul S. Sidhu BSc MBBS MRCP FRCR DTM&H
Consultant Radiologist and Senior Lecturer
King's College London
Department of Radiology
King's College Hospital
Denmark Hill
London SE5 9RS
United Kingdom
Tel: ++44 (0) 20 3299 3063
Fax: ++44 (0) 20 3299 3157
E-mail: paulsidhu@nhs.net

Content

Content	2
Introduction	3
Sonographic examination technique	3
Gross Anatomy	4
Embryology	4
Scrotal sac and testicular anatomy	4
Vascular anatomy	4
Sonographic appearances	5
Normal Variants	7
Trans-mediastinal artery	7
Two-tone testis	8
Rete testis	8
Appendix testis	9
Polyorchidism	9
Acute painful scrotum	10
Inflammatory disease	11
Epididymo-orchitis and Epididymitis	11
Chronic epididymitis	13
Orchitis	13
Trauma	14
Torsion	15
Spermatic Cord Torsion	15
Torsion of an Appendage	16
Fournier's Gangrene	17
Testicular Lumps	18
Intratesticular masses, benign focal lesions	18
Epidermoid Cyst	18
Adrenal rest cells	19
Segmental Infarction	19
Splenogonadal fusion	20
Sarcoidosis	20
Focal orchitis and testicular abscess	21
Intra-testicular haematoma	21
Post-operative and post-biopsy testis	22
Intra-testicular cysts	23
Tunica albuginea cyst	23
Tunica Vaginalis Cyst	24
Dilatation of the Rete Testis	24
Cystic Dysplasia of the Testis	25
Testicular Prosthesis	25
Atrophy	26
Malignant focal lesions	26
Germ Cell Tumours	27
Seminomatous Germ Cell Tumours	27
Non Seminomatous Germ Cell Tumours	28
Non-Germ Cell Tumours	30
Extra-testicular masses	32
Epididymal focal lesions	32

Scrotal calcification.....	36
Testicular microlithiasis and macrocalcification	36
Extra-testicular calcification	38
Extra-Testicular Non-Focal Lesions	39
Scrotal Wall Abnormalities.....	41

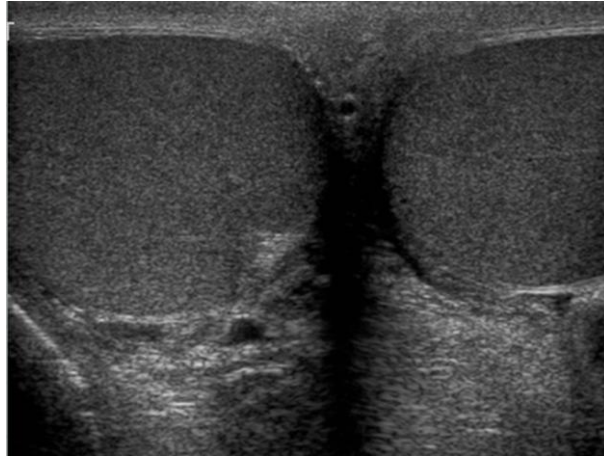
Introduction

Imaging the contents of the scrotum remains firmly within the realm of ultrasonography despite the introduction and extensive use of more sophisticated imaging techniques. Ultrasonography is the first-line and frequently the only imaging modality employed in the assessment of scrotal abnormalities. Technical advances in transducer design and image processing has further improved the quality of diagnosis of diseases of the scrotal contents, with colour Doppler adding important information and newer techniques (contrast-enhanced ultrasound and elastography) awaiting further evaluation. This chapter will deal with aspects related to the testis and epididymis, detailing with both normal sonographic features and those features related to disease processes.

Sonographic examination technique

Private surroundings are essential for the examination which should be conducted in the presence of a chaperone, with the examiner using a gloved hand for the examination. The sonographic gel should be warm with ample amounts applied. The scrotal sac may be stabilized by placing a towel beneath the sac with the penis held against the abdominal wall by the patient. A high-frequency linear array probe should be used, with colour and spectral Doppler capabilities. An adequate transducer length (>5cm) is required to allow accurate longitudinal length measurements of the testis. The 'spectacle' view of both testes in the transvers direction allows comparison of testicular parenchyma features; important if a unilateral global testicular problem is suspected (Figure 1). The entire scrotal sac should be examined in order to include both the transverse and longitudinal planes. Testicular volume may be calculated and colour Doppler sonography will confirm vascular supply. If the examination fails to detect the 'lump', the patient should find the lesion and hold this between two fingers to be re-examined.

Figure 1 Normal Testis. A transverse view through both the testes, the 'spectacle view' allows comparison of the reflectivity of the two testes; of particular importance in infiltrative lymphoma and leukaemia.



Gross Anatomy

Embryology

Over the seventh month of fetal development the testes descend into the scrotal sac with a dense layer of fibrous connective tissue that covers the testis, the tunica albuginea. The testis is also covered by a fold of the processes vaginalis which becomes the visceral layer of the tunica vaginalis, with the remainder of the peritoneal sac forming the parietal layer of the tunica vaginalis. The visceral layer of the tunica vaginalis covers the testes and the epididymis, whereas the parietal reflection covers the anterior and lateral parts of the testes and the epididymis leaving a “bare area” to which the mesentery of the testis is attached, important as the “bell-clapper” deformity in spermatic cord torsion. A reflection of the tunica albuginea forms the mediastinum testis, within which the rete testis forms (1).

Scrotal sac and testicular anatomy

The layers of the scrotal sac consist of skin, dartos muscle, external spermatic fascia, the cremasteric fascia and the internal spermatic fascia. The scrotum is divided into two separate chambers by the median raphe, which is continuous with the dartos muscle. Beneath the internal spermatic fascia is the parietal layer of the tunica vaginalis. A potential space exists between the parietal and visceral layers of the tunica vaginalis allowing fluid accumulation. The visceral layer of the tunica vaginalis covers the inelastic tunica albuginea, which gives rise to multiple thin septations which extend to the mediastinum testis dividing the testis into 200-250 lobules, containing the seminiferous tubules. The seminiferous tubules form the tubuli recti that enter the mediastinum as the rete testis, eventually draining into the epididymis and then into the vas deferens. The epididymis consists of three segments; the head, the body and the tail. The head is formed of efferent ductules from the rete testis, forming a single convoluted duct, the ductus epididymis, up to 6 meters in length. The ductus epididymis has a very tortuous route from the head to the tail of the epididymis, where it turns around to exit into the spermatic cord from the epididymal head.

Vascular anatomy

The arterial supply to the scrotal sac and contents arise from three sources: the *testicular artery*, (arising from the aorta and supplying the testis), the *cremasteric artery*, (a branch of the inferior

epigastric artery, supplying the scrotal sac and the coverings of the spermatic cord), and the *artery to the ductus deferens* (arising from the superior vesicle artery). The testicular artery branches into the testis, piercing the tunica albuginea in a layer termed the tunica vasculosa. These branches course along the septum to converge on the mediastinum and then form recurrent rami through the parenchyma. Veins exit the testes at the mediastinum; join the veins draining the epididymis to form the pampiniform plexus at the superior aspect of the testes. The cremasteric plexus (mainly draining extra-testicular blood) lies posterior to the pampiniform plexus. The right testicular vein drains directly into the inferior vena cava below the level of the right renal vein, whereas the left testicular vein drains into the left renal vein. These three arteries and the veins are loosely held together by connective tissue along with nerves, lymph vessels and the vas deferens in the spermatic cord. The spermatic cord runs from the deep inguinal ring into the scrotum. Although it is not possible to identify a named artery within the spermatic cord, colour Doppler is able to demonstrate the three individual arteries within the spermatic cord. Despite anastomoses existing between the testicular, deferential and cremasteric arteries, one of the arteries will consistently show a significantly lower resistive index than the other two arteries (2).

Sonographic appearances

The scrotal wall appears as three layers; an outer hyper-reflective layer a hypo-reflective intermediate and a hyper-reflective inner layer corresponding to the tunica albuginea. The testes are homogenous and of medium level reflectivity. At birth the testis measures approximately 1.5cm in length and 1.0cm in width, and before 12 years of age the testicular volume is 1-2mLs. In the adult, testicular length may be up to 5cm. Volume measurement is calculated using the formula; length x width x height x 0.51. A total volume (both testis) of >30mLs is indicative of normal function (3). A testicular volume >2mLs allows reliable appreciation of intra-testicular colour Doppler flow (4). The mediastinum testis is seen as a highly reflective linear structure at the posterior-superior aspect of the testicle, draining the seminiferous tubules of the testes into the rete testis (Figure 2). The rete testis is a low reflective area at the hilum of the testis with finger-like projections into the parenchyma (Figure 3) (5). The appendix testis (a vestigial remnant of the Müllerian duct) is present in the majority of patients at the superior testicular (6). There is marked variation in the size and appearance of an appendix testis; usually oval, although a stalk-like cystic structure (cyst of Morgagni) is occasionally seen (Figure 4).

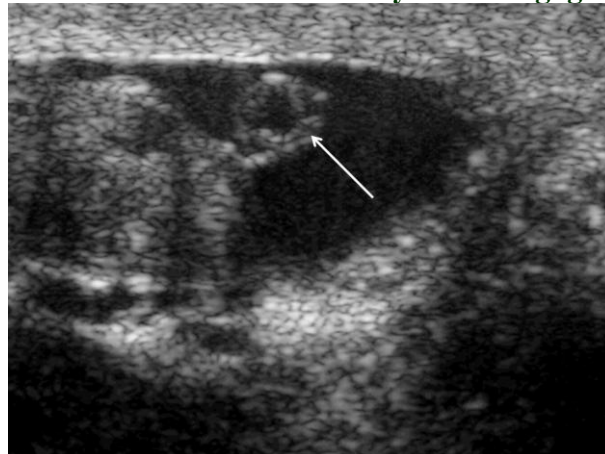
Figure 2 Mediastinum Testis. The mediastinum testis is seen as a highly reflective linear structure at the posterior-superior aspect of the testicle (arrows).

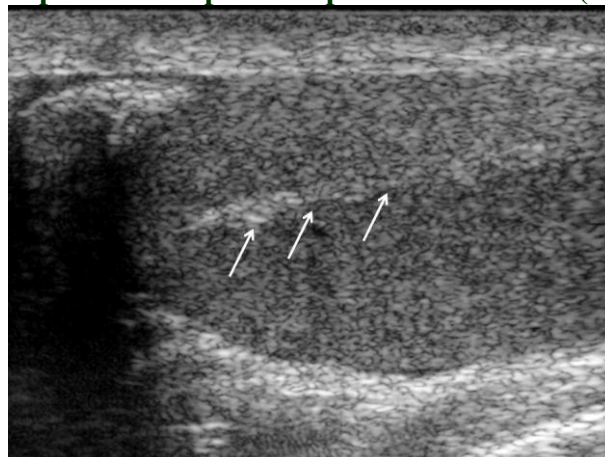

Figure 3 Normal Rete Testis. The rete testis is a low reflective area at the hilum of the testis with finger-like projections into the parenchyma (arrows).

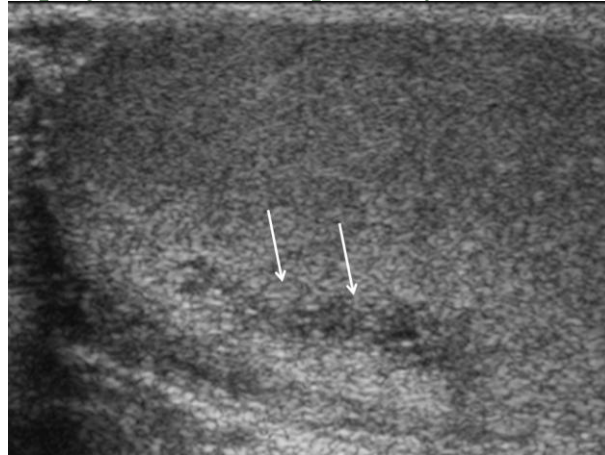

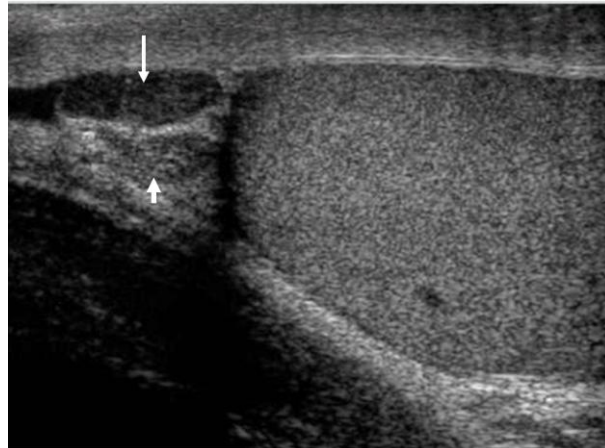
Figure 4 Appendix Testis and Epididymis. There is marked variation in the size and appearance of an appendix testis and epididymis; usually oval, although a stalk-like cystic structure is referred to as the 'cyst of Morgagni' (arrow).



The epididymal head is a pyramid shaped structure lying superior to the upper pole of the testis. The body courses along the postero-lateral aspect of the testicle. The epididymal tail is thicker than the body and is a curved structure at the inferior aspect of the testicle. The body and tail are of slightly lower reflectivity when compared with the testis, whilst the head is of slightly higher reflectivity (Figure 5). Colour Doppler signal may be identified in the normal epididymis (7). The appendix epididymis is not as frequently seen as the appendix testis (8). It is part of the mesonephric (Wolffian duct), and projects from the epididymis from different sites, most commonly the head. The epididymal head measures 10-12mm in diameter, the body less than 4mm (average 1-2mm) in diameter (9).

Figure 5 Normal Epididymal Head. The normal triangular shaped epididymal head. The changes in reflectivity of the epididymis are demonstrated; the low reflectivity of

the body (long arrow) alters in the head of the epididymis (short arrow) to a higher reflectivity.

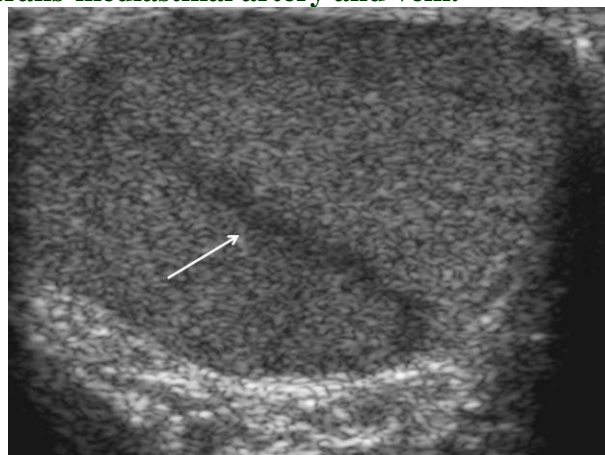

Normal variants

Trans-mediastinal artery

A trans-mediastinal artery is a large branch of the testicular artery that splits off and traverses the testis to form capsular branches at the opposite aspect has been reported 52% of patients, unilateral in half (10). The artery is freely identified with colour Doppler sonography and normally returns a low-resistance spectral Doppler waveform. The trans-mediastinal is often accompanied by the trans-mediastinal vein (Figure 6).

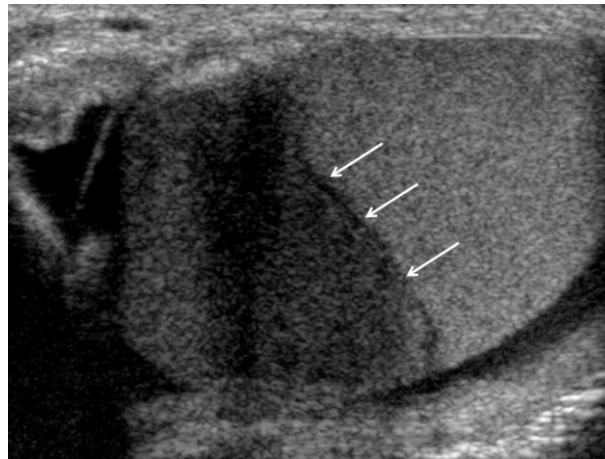
Figure 6 Trans-mediastinal artery and vein. Linear low reflective structure traverses the testis (arrow); the trans-mediastinal artery and vein.



Two-tone testis

The term 'two-tone' describes the appearances of an artefact where the trans-mediastinal artery produces acoustic shadowing resulting in a discreet uniform area of decreased reflectivity posterior to the artery (Figure 7). This artefact is caused by refractive shadowing at both edges of the intra-testicular artery (11). The reflectivity of the remainder of the testis is normal. The use of colour Doppler sonography confirms the presence of the intra-testicular artery as being the source of the artifact (12).

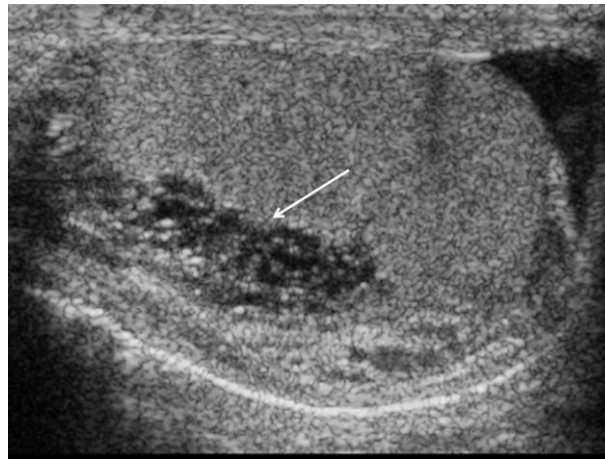
Figure 7 'Two-tone' testis. There is a well demarcated low reflective appearance generated through the testis (arrows) which does not appear to be related to a pathological cause.



Rete testis

The rete testis is contained within the mediastinum testis. On ultrasonography, the rete testis has a spectrum of appearances ranging from a faintly visible ill-defined area of decreased reflectivity (18% of patients) at the testicular hilum to a coarse tubular appearance with finger like projections into the parenchyma (Figure 8) (5).

Figure 8 Rete Testis. An example of a rete testis, with a number of cysts of varying size present adjacent to the mediastinum of the testis (arrow).



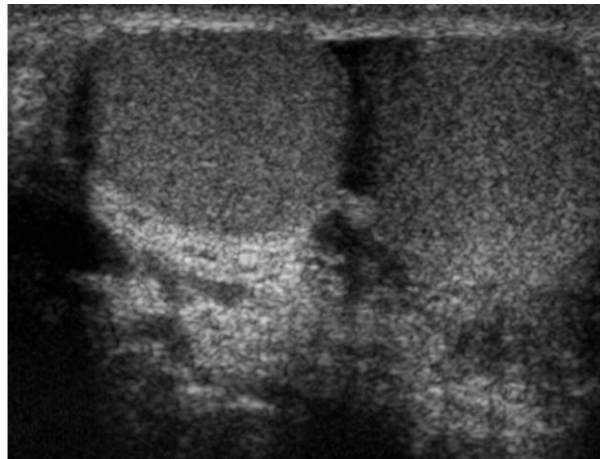
Appendix testis

A remnant of the paramesonephric and mesonephric ducts may remain to form the appendix testis (hydatid of Morgagni) and appendix epididymis respectively. The appendix testis may be present in up to 92% of patients, bilateral in 69% (13). The appendix testis is usually of similar reflectivity to the head of the epididymis, best seen in the presence of a hydrocoele, most commonly being oval shaped and sessile but it may appear 'stalk like' and pedunculated, cystic or calcified (6). The 'stalk like' and cystic appendices are linked with an increased possibility of appendiceal torsion recognized as a cause of acute scrotal pain (14). The epididymal appendix is less frequently seen (6%), is more frequently stalked and may undergo torsion, although less commonly (13). On occasion both an epididymal and testicular appendage may be seen in the same patient.

Polyorchidism

Polyorchidism (more than two testes) is a rare condition and most commonly involves a bifid or duplicated testis with a single epididymis, with a uniform surrounding tunica albuginea (Figure 9) (15;16). Polyorchidism, usually presents as a painless mass and occurs more often on the left. The supernumerary testes may or may not have reproductive potential depending on the attachment to a draining vas deferens and epididymis; type 1 with reproductive potential and type 2 with no reproductive potential (17). Based on the embryological development polyorchidism may be classified into 4 types (18); **Type A:** the supernumerary testis lacks either an epididymis or vas deferens, **Type B:** the supernumerary testis has an epididymis but no vas deferens and the epididymis may be connected to the normal ipsilateral testis (Type B2) or have no connection (Type B1), **Type C:** the supernumerary testis has a separate epididymis but shares the vas deferens with the ipsilateral testes either in a parallel or longitudinal fashion, **Type D:** the supernumerary testis may have a completely separate epididymis and vas deferens and is the least common.

Figure 9 Polyorchidism. The left testis is divided into two components both of the normal reflectivity of a testis.



The sonographic features are those of a well-defined rounded lesion occurring either superior or inferior to the ipsilateral testicle with identical reflectivity and colour Doppler signal as the ipsilateral testis (19). The length of the two ipsilateral testes added together equates to the length of the contra lateral testicle. Polyorchidism has been reported in association with rete testis and microlithiasis (20). Various malignancies have been reported in the supernumerary testes (21;22). Management is conservative.

Acute painful scrotum

Acute scrotal pain [Table 1] is a common urological emergency for which epididymo-orchitis is the commonest cause, but the most important diagnostic distinction to be made is between acute spermatic cord torsion and the other causes of acute scrotal pain. The treatment for acute spermatic cord torsion is urgent surgical exploration to maintain viability of the testis and avoid testicular infarction. Diagnostic accuracy is important in order to identify those patients that require immediate surgical intervention and to avoid unnecessary surgery in patients with a non-surgical cause for acute testicular pain. Clinical examination can be particularly inaccurate in distinguishing the causes of acute scrotal pain; in particular, the clinical discrimination between acute epididymo-orchitis and spermatic cord torsion can be practically unattainable. In the emergency setting, the ready availability of gray scale and colour Doppler allows ultrasonography to remain the imaging modality of choice. Familiarity with the sonographic features of common causes of acute scrotal pain is therefore a necessity for the emergency on-call radiologist in order to provide complementary information for the clinical team to aid accurate diagnosis in these patients.

Table 1 Causes of acute scrotal pain

- Acute epididymo-orchitis
- Chronic epididymo-orchitis
- Acute spermatic cord torsion
- Intermittent torsion of the spermatic cord
- Acute testicular trauma
- Acute segmental testicular infarction
- Henoch Schonlein purpura
- Patent processes vaginalis with acute appendicitis
- Intra-testicular tumours

Inflammatory disease

Epididymo-orchitis and epididymitis

Epididymo-orchitis and epididymitis predominantly affects the sexually active male of less than 40 years, the older patient with urological disease and the pre-pubertal boy with an associated urogenital anomaly (23). The main causative organisms in sexual transmitted diseases are *Chlamydia trachomatis* and *Neisseria gonorrhea*, whereas in pre-pubertal boys and in men over the age of 40 years, the organisms responsible are *Escherichia coli* and *Proteus mirabilis*. Epididymitis causes acute scrotal pain of varying intensity, pyuria with fever and at clinical examination the epididymis may be palpated as a thickened tender structure separate from the testis.

The sonographic features are characteristic; the epididymis may be involved in focal areas (often the lower is affected first) or in a global pattern, with enlargement, decreased reflectivity and increased colour Doppler flow (Figure 10) (24;25). The increased colour Doppler flow to the inflamed epididymis is the mark for hyperemia and conveniently aids the diagnosis of epididymitis. There is often a reactive hydrocele, with septations if a pyocele develops and scrotal wall thickening (Figure 11). The infection may spread to the adjacent testis (epididymo-orchitis), seen as patchy areas of low reflectivity and increased colour Doppler signal, an appearance that may persist for several months following treatment, sometimes difficult to exclude a malignant lesion (Figure 12) (26). It is important that diffuse heterogeneous hyper-reflectivity and focal changes of the testes in suspected orchitis be followed up to ensure complete resolution and rule out neoplasm (27).

Figure 10 Epididymitis. The epididymis is enlarged and of mixed reflectivity (arrows).

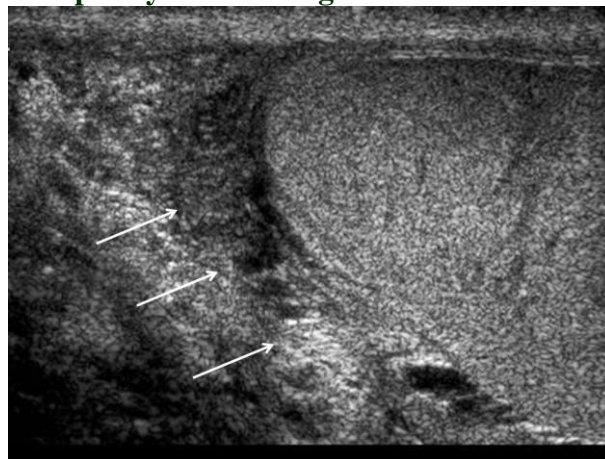


Figure 11 Pyocele. There is a septated, mixed reflective hydrocele (short arrow) with thickening of the overlying scrotal skin (long arrows).

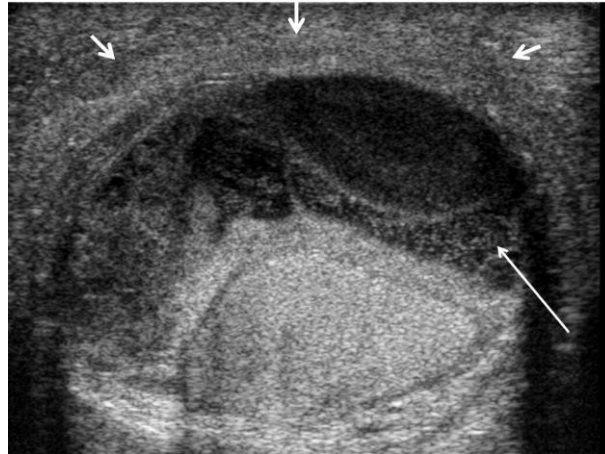
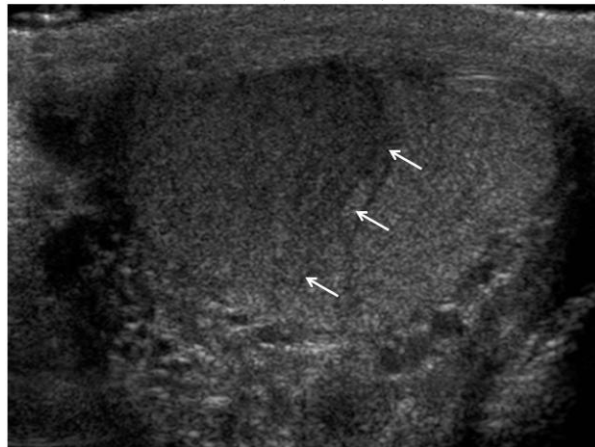


Figure 12 Epididymo-orchitis. A focal area of orchitis in a patient with epididymo-orchitis mimicking a focal testicular mass (arrows).



Venous infarction of the testis may occur in patients with severe epididymo-orchitis where localised oedema occludes the venous drainage of portions of the testis or the entire testis (Figure 13) (28;29). Other complications include abscess formation (low reflective area surrounded by increased colour Doppler signal) (Figure 14), testicular atrophy and chronic pain.

Figure 13 Venous Infarction. There is an area of irregularity and mixed reflectivity present in the posterior aspect of the testis (arrow) in a patient with severe epididymitis.

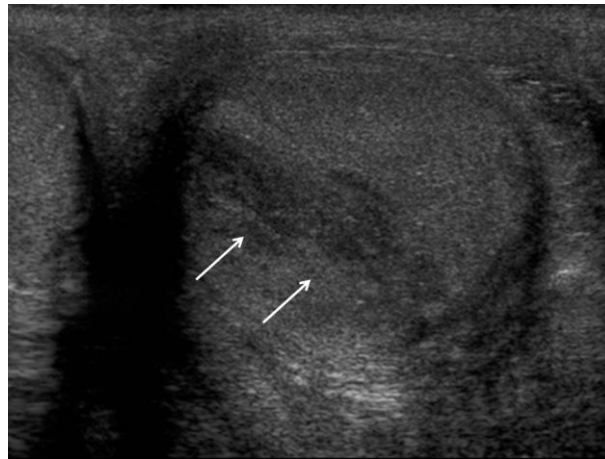
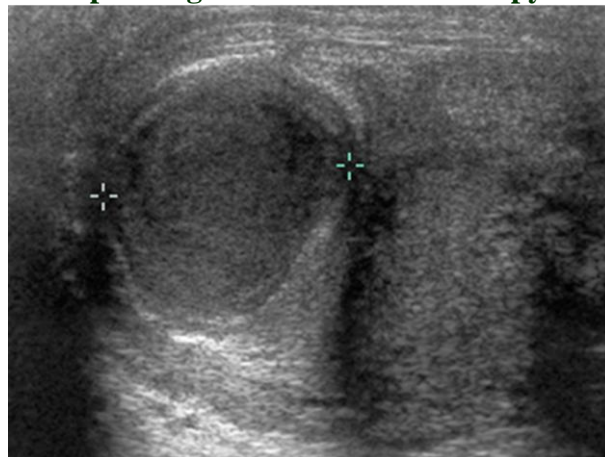


Figure 14 Epididymal Abscess. There is a focal area of mixed reflectivity (between cursors), containing debris, in the head of the epididymis in a patient with acute epididymitis not responding to anti-bacterial therapy.



Chronic epididymitis

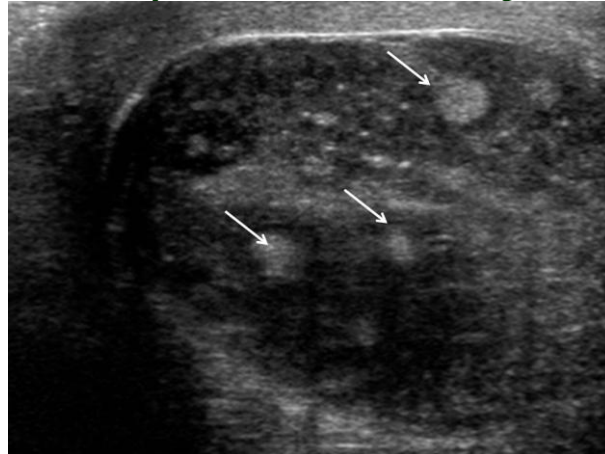
Chronic epididymitis results in persistent pain and on sonography an enlarged epididymis with increased reflectivity and calcification is often present. Tuberculosis epididymitis may present in a similar manner to bacterial epididymitis but will not respond to standard antibiotic treatment (30). Sonographic features are not specific, although chronic disease with calcification and indolent abscess formation discharging onto the skin may be present (31;32).

Orchitis

Most commonly there is involvement from acute epididymitis resulting in a combination of epididymitis and orchitis. Primary orchitis without associated epididymitis is comparatively rare but may be caused by HIV or mumps virus (33). An inordinate array of appearances is seen on sonography in acute orchitis. Initially oedema of the testis arises with associated pain, with sonographic appearances those of a diffuse low reflective pattern (26). The appearances then develop to areas of low reflectivity with an increase in colour Doppler flow (24). As the condition progresses, areas of venous infarction occur with associated haemorrhage, giving rise to areas of

mixed or increased reflectivity (34). Complications include abscess formation, infarction and necrosis (Figure 15). Following treatment and healing, changes may resolve completely or often there is loss of volume of the testis with fibrosis giving a heterogeneous sonographic pattern (26).

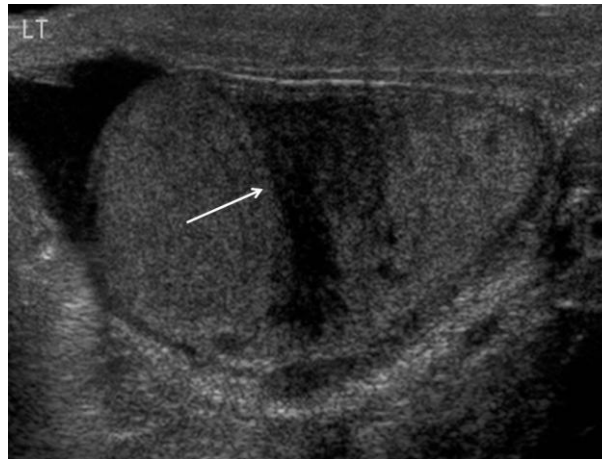
Figure 15 Complicated Orchitis. There are multiple areas of high reflectivity (arrows) in this mixed but predominantly low reflective testis in a patient with severe orchitis.



Trauma

Testicular trauma is usually seen following motor vehicle accidents, athletic injury or a straddle injury. The mobility and elasticity of the scrotal tissues provides protection for the testis in the event of trauma. However, forceful compression of the scrotal contents against the pubic ramus or impact with objects moving at high velocity can result in serious injury. Blunt scrotal trauma may result in a variety of injuries including testicular rupture, torsion, dislocation, haematoma or contusion. Epididymal, scrotal wall and urethral injury may also be seen. Pain and swelling of the scrotum following trauma makes clinical examination extremely difficult. Ultrasonography is useful in the context of trauma and can help to exclude or confirm testicular rupture and differentiate testicular haematoma from haematocele. Testicular rupture is a surgical emergency, which on sonography is manifest by discontinuity of the tunica albuginea, irregular heterogeneous testicular margins, a haematocele and diminished colour Doppler flow to the affected area (35;36). Direct visualization of a fracture site is unusual, more often parenchyma heterogeneous areas are seen (Figure 16). A haematoma will initially be seen as a high reflective area but with progression of the haematoma over time will subsequently manifest as a low reflective complex cystic structure.

Figure 16 Testicular Trauma. Ultrasonography of the testis following trauma demonstrating a fracture line (arrow) through the mid-aspect of the testis.



Torsion

Spermatic cord torsion

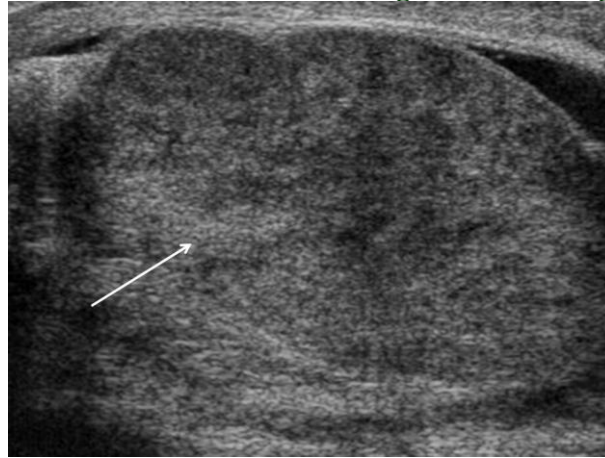
Testicular infarction occurs when the spermatic cord is twisted, termed spermatic cord torsion (37). A narrow mesenteric attachment from the spermatic cord to the testes and epididymis is regarded as the main cause, allowing the testes to fall forward within the cavity of the tunica vaginalis and then to rotate like a “bell-clapper”; the “intra-vaginal” type of torsion (38). In neonates the entire testes, epididymis and the tunica vaginalis twist in a vertical axis on the spermatic cord; termed “extra-vaginal” torsion (39). Neonatal torsion is rare occurring in the prenatal period and associated with an inguinal hernia (40).

Two factors are of importance in spermatic cord torsion: the extent of the spermatic cord twist and the duration of the torsion, with the initial disruption to the venous and lymphatic drainage, rather than to the arterial supply of the testes, and venous infarction occurs earlier (28). Scrotal oedema is an early feature, and areas of testicular infarction appear within 2 hours of complete occlusion of the testicular artery, irreversible ischemia occurs after 6 hours and complete infarction by 24 hours (41). Intra-vaginal torsion most commonly occurs between 12-18 years, with a reported incidence of 1 in 4000 males (42). Torsion commonly arises as puberty approaches, when testicular volume increases.

Clinically intra-vaginal torsion presents with pain of sudden or insidious onset and is followed by swelling of the ipsilateral scrotum, the clinical quandary the difference between spermatic cord torsion and acute epididymo-orchitis. Establishing the diagnosis is important; in acute epididymo-orchitis, resolution with minimal intervention is the rule unless complications supervene whereas surgery is mandatory for torsion. The diagnostic dilemma is compounded by the similarity in clinical presentation as fever and pyuria may occur in both conditions (43).

The sonographic appearances of the testis following spermatic cord torsion are variable depending on the time elapsed from the onset of symptoms. With the development of congestion and infarction, the testes appear enlarged with decreased reflectivity (44) (Figure 17). As infarction is established, haemorrhage may increase reflectivity and heterogeneity; particularly in missed torsion and “chronic” torsions (symptoms present for more than 10 days). There may be an abrupt change in caliber of the spermatic cord below the point of torsion which results in an enlarged, twisted spermatic cord superior and posterior to the epididymal head, containing round anechoic structures representing veins resembling a ‘whirl-pool’ first described with MR imaging (45;46).

Figure 17 Spermatic Cord Torsion. The testis is enlarged and heterogeneous (arrow).



The basis for the sonographic analysis of spermatic cord torsion is the absence of colour Doppler flow in the symptomatic testis compared to the asymptomatic testis, whereas it may be increased in epididymo-orchitis (24;47). Colour Doppler ultrasound is useful in promptly differentiating acute spermatic cord torsion from epididymo-orchitis. Although colour Doppler is of worth in the adult testes it is less sensitive for the detection of blood flow in children; symmetry of blood flow is dependent on testicular size (4). A drawback with colour Doppler ultrasound is the entity of severe epididymo-orchitis complicated by testicular infarction (48). A reversal of diastolic flow in the testicular artery is thought to be characteristic of venous thrombosis, and when combined with the gray-scale and colour Doppler appearances of the inflamed epididymis, should allow a correct analysis to be reached (49;50). There is however, no single clinical feature or imaging examination that can reliably distinguish torsion from other causes of testicular pain (51).

A pit-fall of the use of colour Doppler ultrasound in the assessment of the acute scrotum, and in the desire to exclude the presence of spermatic cord torsion, is the entity of a spontaneous de-torsion. The susceptible testis undergoes torsion, and then spontaneously un-twists, resulting in hyperaemia of the previously ischaemic testis. On sonography, the B-mode appearances may be unexceptional, but an increase in colour Doppler flow may resemble acute epididymo-orchitis; resulting in a misinterpretation.

Torsion of an appendage

Torsion of the testicular (or epididymal) appendage is more common than spermatic cord torsion and an important differential diagnosis among boys under the age of 13 years with an acutely painful scrotum. Although most frequently presenting in patients under the age of 13 years, torsion of a testicular appendage can occur at any age and may present in adulthood. The onset may be associated with trauma or exercise with pain, erythema, tenderness and scrotal swelling common presenting symptoms (51). In light-skinned individuals the palpable, inflexible, tender appendage may be visible at the upper pole of the testis; this 'blue-dot' sign (52).

With torsion of a testicular appendage, the testis itself usually appears normal on sonography. There is an upper pole hydrocele and an inflammatory reaction in the epididymis, which is often enlarged. The torsed appendage may have a variable appearance; most commonly of increased homogenous reflectivity, but not infrequently of low reflectivity surrounded by an area of increased colour Doppler flow (Figure 18) (47). With time the appendix becomes increasingly of higher reflectivity, indicating the onset of calcification, eventually completely detaching itself (Figure 19).

Figure 18 Torsion of the Appendix Testis. A hydrocele surrounds the upper aspect of the testis, with a prominent appendix testis (arrow) seen; appearances are those of torsion of an appendix in a patient with the appropriate symptoms of sudden onset of testicular pain.

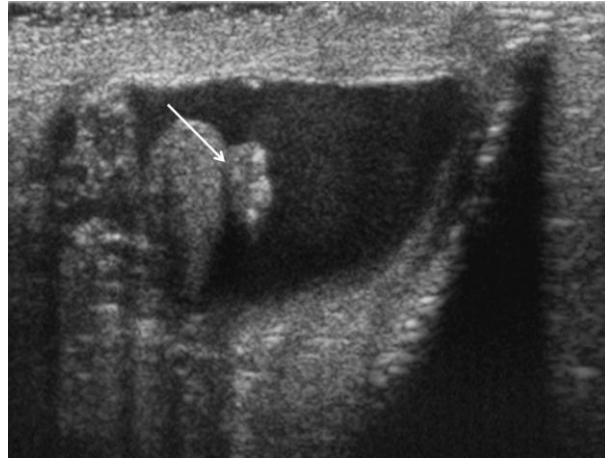
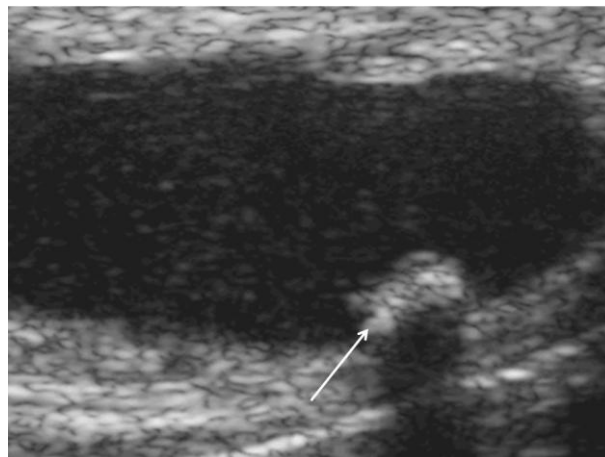


Figure 19 Detached Appendix Testis. With time the appendix becomes increasingly of higher reflectivity, indicating the onset of calcification, eventually completely detaching itself.

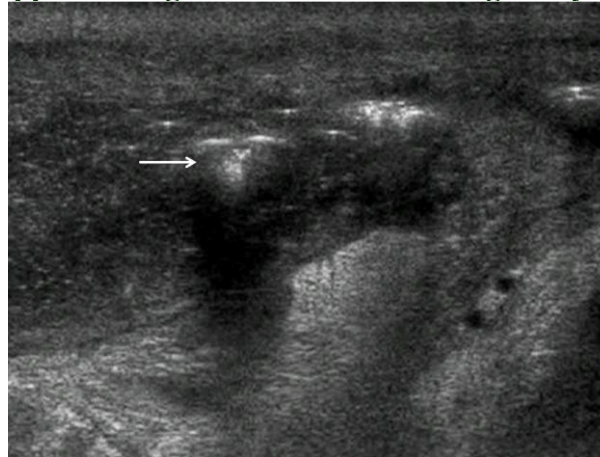

Fournier's gangrene

Fournier's gangrene is an aggressive necrotising fasciitis of the perineum, occurs in males aged 50-70 years, associated with diabetes mellitus (53). Fournier's gangrene arises secondary to local infection with multiple different organisms; *Klebsiella*, *Streptococcus*, *Proteus* and *Staphylococcus* are frequently described (54). Immediate surgical resection of the devitalised tissues is needed as the condition carries a high morbidity and mortality rate. Prompt diagnosis is vital; mortality increases to 11.5% at 24 hours diagnostic delay and a diagnostic delay of 6 days results in a mortality rate of 75% (55). Anaerobic bacterial metabolism produces soft tissue gas that can be detected clinically as crepitus and on sonography much earlier (56). Sonographic features of Fournier's gangrene are

scrotal wall thickening containing multiple pockets of gas, which appear as high reflective foci causing 'dirty shadowing' with normal underlying testes (57) (Figure 20).

Figure 20 Fournier's Gangrene. Ultrasound of the scrotal wall demonstrates multiple pockets of gas which appear as high reflective foci causing 'dirty shadowing' (arrow).



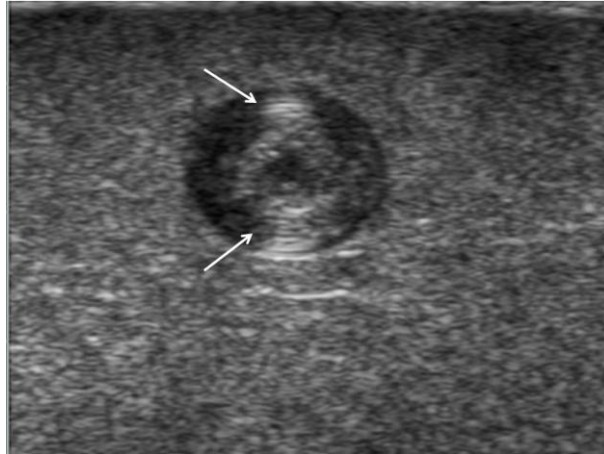
Testicular lumps

Intratesticular masses, benign focal lesions

Epidermoid cyst

These are benign lesions with no malignant potential accounting for 1% of intra-testicular lesions (58). An epidermoid cyst either arises from monodermal development of a teratoma or as a result of squamous metaplasia of surface mesothelium. Epidermoid cysts are true cysts, containing a cheesy laminated material. Patients present between 20-40 years of age, with a mass but often as an incidental finding on a sonographic examination. Classically epidermoid cysts are well-circumscribed with a high reflective border and internal laminations giving an 'onion-ring' appearance (Figure 21) (59). There is no colour Doppler flow detected within the lesion. Four sonographic types are documented i) classic onion ring configuration ii) densely calcified mass iii) peripheral rim or central calcification iv) mixed pattern (58). Management is either by enucleation or orchidectomy and as the sonographic findings are frequently non-specific, orchidectomy is often performed.

Figure 21 Epidermoid Cyst. An epidermoid cyst, demonstrating a well-circumscribed low reflective appearance with a high reflective border and internal laminations (arrows) giving an 'onion-ring' appearance.



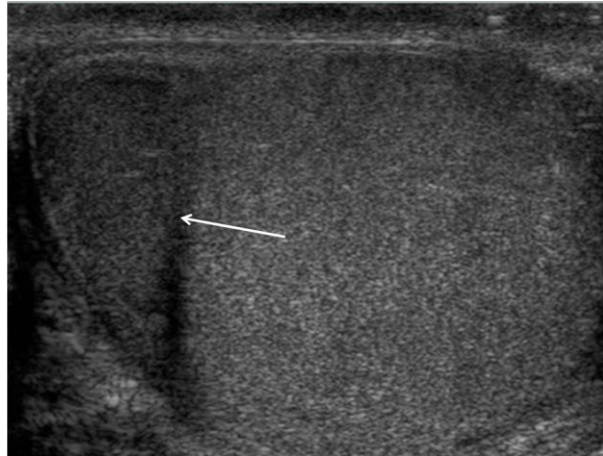
Adrenal rest cells

Testicular adrenal rest tumors are benign adenocorticotrophic hormone (ACTH)-dependent lesions that are asymptomatic and occur in patients with congenital adrenal hyperplasia. Increased ACTH levels prevent involution of aberrant adrenal cortical cells that migrate with gonadal tissues in fetal life. The testicular adrenal rests are usually less than 5 mm and these ectopic adrenal rest cells within the testis develop as a tumour-like abnormality only in response to elevated circulating ACTH. Furthermore the intra-testicular nodules of adrenal rests can gradually expand and destroy the testicular parenchyma, resulting in low testosterone production and infertility. Treatment with steroid therapy can stabilize or regress these lesions, and aids the diagnosis. These tumours usually appear as focal low reflective abnormalities with abnormal colour flow and are often bilateral (60;61).

Segmental infarction

Global testicular infarction is well recognized, usually as a result of torsion of the spermatic cord (51). Segmental testicular infarction is however rare and is usually diagnosed following orchidectomy (62). The majority of cases are idiopathic in origin (63;64). Patients with segmental infarction tend to be older than those with testicular infarction arising from spermatic cord torsion, usually between 20-40 years. Segmental testicular infarction is characterized by poor or absent flow on colour Doppler ultrasound in a focal low reflective wedge-shaped or rounded area with no posterior acoustic enhancement (Figure 22) (64). Focal expansion of the testis may mimic a primary testicular tumour and colour Doppler ultrasound provides a useful discriminatory tool (65). Serial sonographic examination of an area of infarction will demonstrate reduction in size of the lesion.

Figure 22 Segmental Infarction. A focal wedge-shaped area of low reflectivity (arrows) in a testis of a patient complaining of acute testicular pain with no evidence of inflammatory disease.



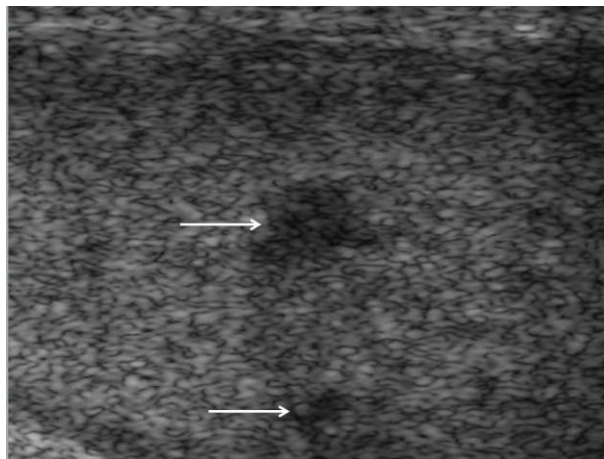
Splenogonadal fusion

Splenogonadal fusion is a rare condition where an accessory spleen exists within the scrotum or pelvis fused to the gonadal organs; the majority of cases occurring on the left side. Splenogonadal fusion is far more common in males, where presentation is usually with a scrotal mass (66). There are two types of splenogonadal fusion described, continuous and discontinuous (67). In the more common continuous type, a cord connects the normal and ectopic spleen; this cord may be beaded with small splenunculi. In the discontinuous type there is no cord present. The sonographic appearance of splenogonadal fusion is that of a mass within the scrotal sac of low reflectivity, which may appear to be fused to the testis (68;69). Colour Doppler ultrasound flow in the abnormal tissue assumes a pattern similar to that seen in the central aspect of the normal testis or that seen in splenic tissue (70). Should the diagnosis be considered, a ^{99m}Tc -sulphur colloid scan will demonstrate uptake within the ectopic splenic tissue.

Sarcoidosis

Sarcoidosis most commonly involves the epididymis; solitary testicular involvement is uncommon (71-73). Differentiation from a primary testicular malignancy is demanding but may be inferred if there is clinical evidence of sarcoidosis elsewhere, if the intra-testicular lesions are multi-focal or if there is associated epididymal involvement. The reported incidence of genital involvement at post-mortem is 4-4.5% but only 0.5% of these patients had clinical symptoms (74). On sonography sarcoidosis appears as a low reflective focal lesion (Figure 23) (72;73).

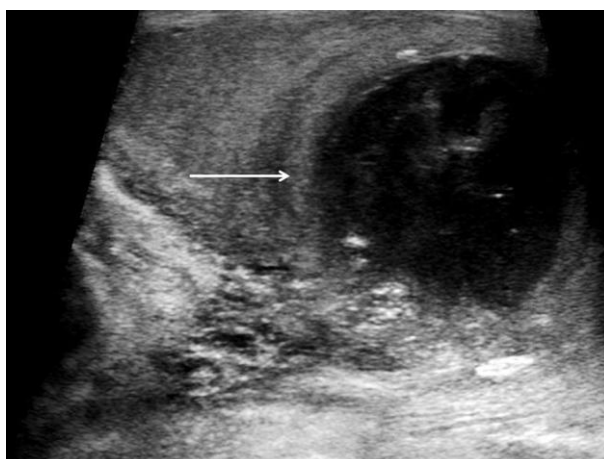Figure 23 Testicular sarcoidosis. Two focal lesions within the testis in a patient with sarcoidosis (arrows).



Focal orchitis and testicular abscess

Pure orchitis is uncommon (usually the result of mumps); the testis is frequently involved when epididymitis occurs resulting in epididymo-orchitis (75). On sonography, the testis is enlarged with either diffuse low reflectivity with pure orchitis or more commonly focal areas of low reflectivity when associated with epididymitis. On occasion a focal abnormality may be produced that mimics a tumour; which should regress with time (Figure 12). Abscess formation may occur, particularly with severe epididymo-orchitis, where the abscess demonstrates low reflectivity and peripheral but no internal colour Doppler signals (Figure 24) (76). If an abscess ruptures through the tunica albuginea, a pyocele may develop. Idiopathic granulomatous orchitis can also present as a focal mass or diffuse enlargement of a testis and is indistinguishable from a tumour at ultrasound.

Figure 24 Intra-testicular Abscess. A focal area of mixed reflectivity (arrow) in a patient with epididymo-orchitis representing a focal abscess.

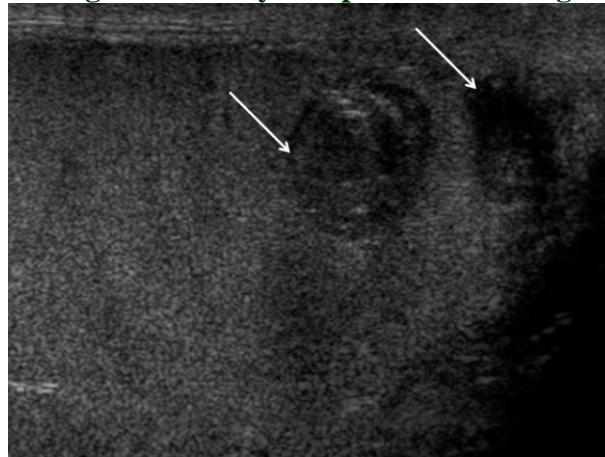


Intra-testicular haematoma

Testicular rupture, extra-testicular haematoma and a haematocele are the most common sequelae of testicular trauma (77). An uncommon finding is an isolated intra-testicular haematoma, which has a variable appearance on sonography with a sequential change in characteristics (78;79). A history of

trauma to the scrotum should be sought. Acutely the haematoma appears as increased reflectivity that becomes low reflective and decreases in size as the haematoma retracts, to eventually resolve completely and demonstrates no colour Doppler flow (78;79). (Figure 25). The differential is from a malignant tumour but a lack of lesion vascularity and the clinical history should lead to the correct diagnosis.

Figure 25 Intra-testicular Haematomas. Two areas of predominantly low reflectivity (arrows) but with areas of high reflectivity in a patient following a motorcycle accident.



Post-operative and post-biopsy testis

Following surgery to the pelvis, prostate and scrotum, oedema of the scrotal wall is a frequent finding causing thickening visible on ultrasound (Figure 26). Often there is oedema of the testicular parenchyma causing a characteristic ‘crazy-paving’ appearance as the oedema follows anatomical boundaries. Following biopsy, a surgical scar may be seen as a localised alteration in parenchymal reflectivity extending to the surface of the testis (Figure 27).

Figure 26 Scrotal Wall Oedema. There is marked thickening of the scrotal wall (arrow) following an inguinal hernia repair.

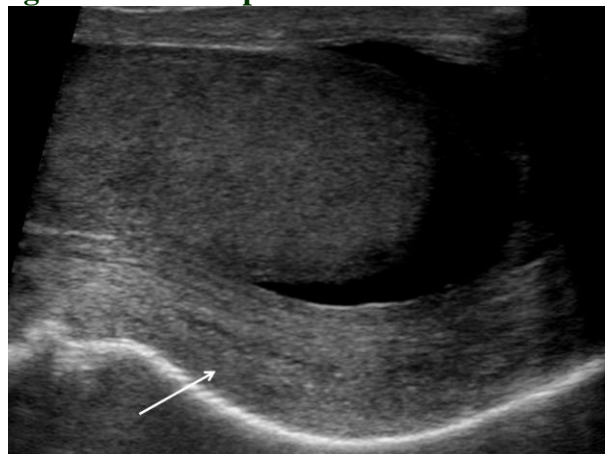
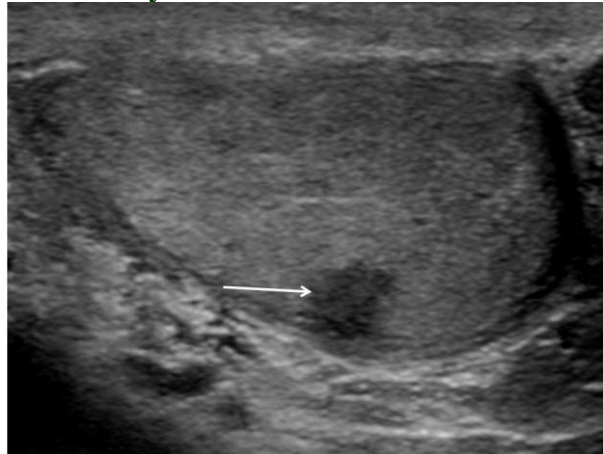


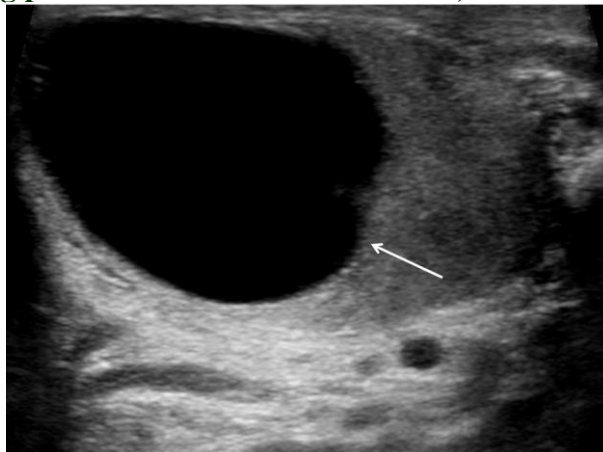
Figure 27 Post-Biopsy ‘Scar’. A focal low reflective ‘scar’ (arrow) following a biopsy in the investigation of infertility.



Intra-testicular cysts

Intra-testicular cysts were thought to be rare but are now seen as incidental findings in 8-10% of sonographic examinations (80). These cysts are rarely palpated and even if large are not firm. Simple cysts are well delineated anechoic round structures, with a thin smooth wall and posterior acoustic enhancement (Figure 28). The intra-testicular cysts may be congenital, or arise post-trauma or post-inflammatory. These cysts are often near the mediastinum testis and may arise from an anomalous efferent duct. Careful sonographic examination to exclude any wall irregularity which may suggest a cystic tumour is needed.

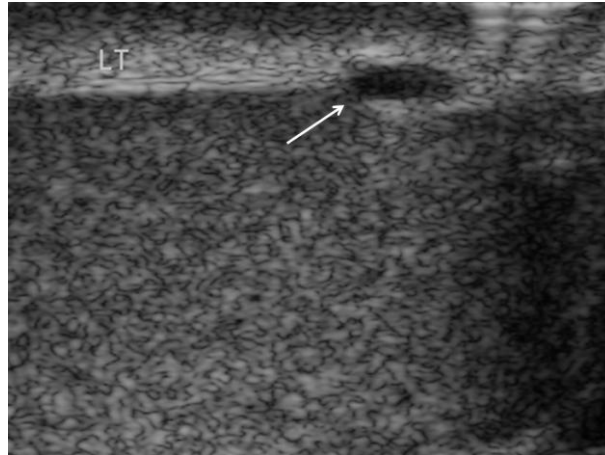
Figure 28 Intra-testicular Cyst. A large low reflective lesion (arrow) within the testis demonstrating posterior acoustic enhancement; a testicular cyst.



Tunica albuginea cyst

Tunica albuginea cysts are located within the dense tissue of the closely adherent tunica albuginea (Figure 29). These cysts are usually solitary, unilocular and readily palpated by the patient as a firm nodule on the surface of the testis.

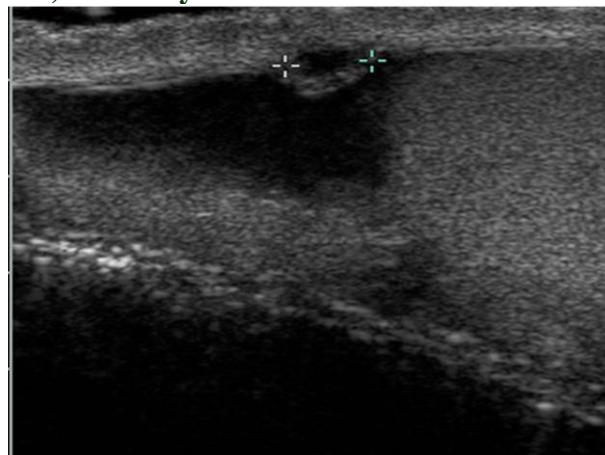
Figure 29 Tunica albuginea Cyst. A small cyst (arrow) is situated in the line of the echogenic tunica albuginea. These tunica albuginea cysts are frequently palpated by the patient and give rise to concern.



Tunica vaginalis cyst

A tunica vaginalis cyst arises from either the visceral or parietal layer of the tunica vaginalis (Figure 30).

Figure 30 Tunica Vaginalis Cyst. In the presence of a hydrocele, this tunica vaginalis cyst (between cursors) is readily visible.

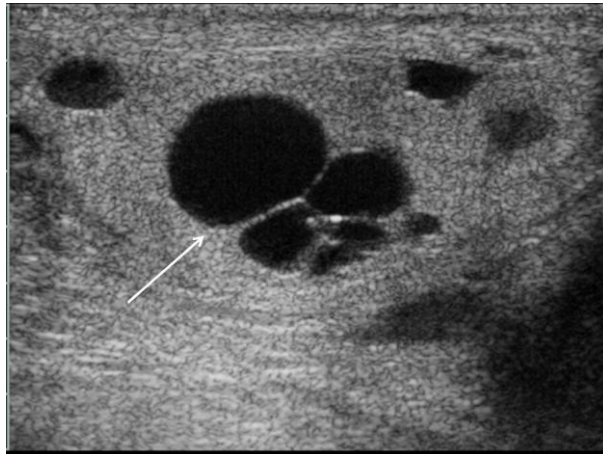


Dilatation of the rete testis

Cystic ectasia of the rete testis results from the partial or complete obstruction of the efferent ducts often by inflammation or trauma, and causes dilatation of the rete testis in an asymmetrical unilateral distribution, though often symmetrically as a normal consequence of aging (Figure 31). The differential diagnosis is of a malignant cystic testicular tumour although the bilateral nature of ectasia usually suggests the diagnosis, and a cystic tumour is exceedingly rare. On sonography appearances of a dilated rete testis are multiple low reflective oval or rounded structures, which do not demonstrate vascular flow within the mediastinum testes (5). The cysts usually measure a few millimetres in diameter but may vary considerably (81). Whilst this is a benign entity it may be

of significance in a patient suffering from infertility and azospermia as there may be obstruction of the ipsilateral spermatic ducts. Distension of the rete testes has been described in association with a seminoma, where the obstruction of the tubules by tumour is thought to be responsible (80).

Figure 31 Dilated Cystic Rete Testis. The central aspect of the testis, along the line of the mediastinum testis there are multiple areas of cystic dilatation (arrow) of varying size in keeping with dilatation of the rete testis. Further cysts are present elsewhere in the testis.



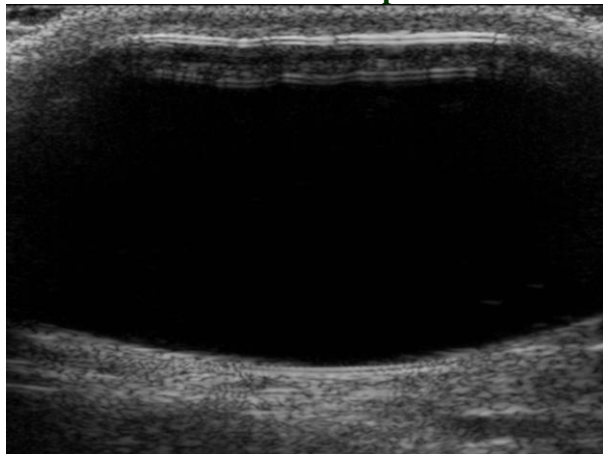
Cystic dysplasia of the testis

Although cystic dysplasia is similar in appearance to a dilated rete testis, this is thought to represent a rare congenital anomaly and is usually diagnosed in childhood (5).

Testicular prosthesis

Following orchidectomy, patients may elect to have a testicular prosthesis inserted, normally made of silicon. A testicular prosthesis has a characteristic appearance on ultrasound (Figure 32).

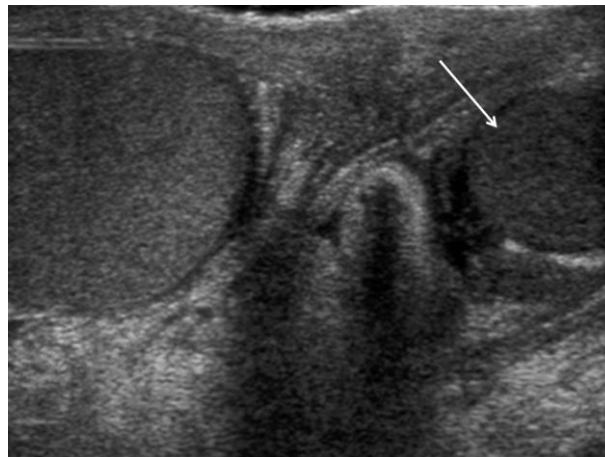
Figure 32 Testicular Prosthesis. A silicone testicular prosthesis of uniform low reflectivity.



Atrophy

Testicular atrophy may occur following cryptorchidism, inflammation, torsion, trauma, hypothyroidism, oestrogen treatment, liver cirrhosis, hypopituitary disease and ageing. The testis is globally reduced in size, usually unilateral with changes in testicular reflectivity related to the underlying cause, but usually of lower reflectivity (Figure 33). While volume and vascularity of the testis are reduced, the epididymis remains normal. Atrophy is a natural phenomenon of ageing where changes in the normal testis reflectivity, usually of a heterogeneous nature, may occur (82).

Figure 33 Testicular Atrophy. Testicular atrophy (arrow) in this spectacle view demonstrating a small low reflective testis.



Malignant focal lesions

Malignant focal lesions are summarized in Table 2.

Table 2 CLASSIFICATION OF TESTICULAR TUMOURS

Germ cell tumours

Precursor lesions

Intratubular germ cell neoplasia

Tumours of one histological type

Seminoma

Classic

Spermatocytic

Embryonal carcinoma

Yolk sac tumour

Choriocarcinoma

Teratoma

Mature

Immature

With malignant transformation

Tumours of more than one histological type

Non-Germ cell tumours (Sex cord and stromal tumours)

Leydig cell tumour

Sertoli cell tumour

Granulosa cell tumour

Fibroma-thecoma

Tumours with both sex cord and stromal cells and germ cells

Gonadoblastoma

Lymphoid and hematopoietic tumours

Lymphoma

Leukaemia

Metastasis

Testicular carcinoma represents 1% of all neoplasm in men and is the most common malignancy in the 15-35 year old age group (83). A second peak prevalence occurs at 70-90 year old age group, with metastasis and lymphoma most common. A third smaller peak occurs in children where yolk sac tumours and teratoma occur. Testicular carcinoma is predominantly a cancer of white males. The most common presenting symptom is a painless scrotal mass; rarely patients present with pain. A small number of patients present with metastases or rarely with endocrine abnormalities such as gynecomastia. Survival rates for testicular carcinoma approach 95% (83).

Risk factors for the development of testicular carcinoma include previous testicular tumour, family history, cryptorchidism, infertility and inter-sex syndromes and even with removal of an undescended testis, there remains an increase in risk in the contra-lateral testis. Testicular tumours may be divided into germ cell and non-germ cell tumours; 95% of testicular tumours are germ cell tumours which arise from spermatogenic cells. Non-germ cell tumours derive from sex cords (Sertoli cells) and stroma (Leydig cells); these tumours are malignant in 10% of cases. Lymphoma, leukaemia and metastases may present as a testicular tumour.

Most testicular tumours are of homogenous, low reflectivity in comparison to the surrounding testicular parenchyma, although a wide range of appearances occur including high reflective, heterogeneous lesions with areas of calcification and cystic change (84). Larger tumours demonstrate increased vascularity (85), although with the newer high frequency transducers, malignant vascularity may be identified in small volume tumours (86;87).

Germ cell tumours

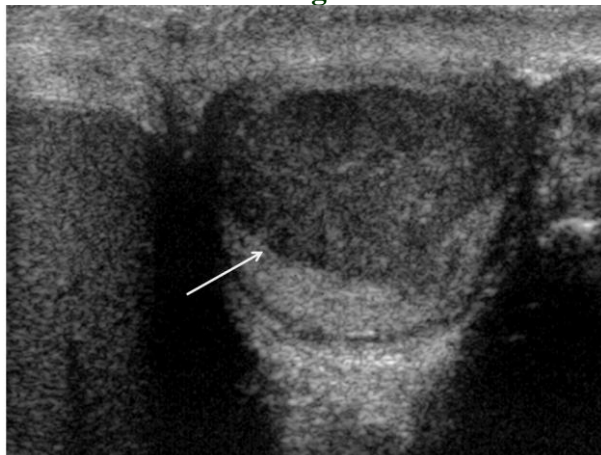
The precursor of germ cell tumours is thought to be intra-tubular germ cell neoplasia; if development is along a 'uni-potential' gonadal line a seminoma will form but if development occurs along a 'toti-potential' gonadal line, a non-seminomatous tumour will develop (88). The 'toti-potential' cells may remain undifferentiated (embryonal carcinoma) develop toward embryonic differentiation (teratoma) or extra-embryonic differentiation (yolk sac tumours, choriocarcinoma). Multiple histological types occur together (mixed germ cell tumour) as these 'toti-potential' cells develop along multiple pathways (89). Tumour markers play an important role in diagnosis, staging, prognosis and follow-up of germ cell tumours; α -fetoprotein is raised in yolk sac tumours and teratomas, human chorionic gonadotrophin is raised in choriocarcinoma (90).

Seminomatous germ cell tumours

Seminoma represents the most common solid tumour in young men with the highest rates reported in Europe, Scandinavia and North America, with a white/black ratio of 5:1. Seminomas are most often associated with cryptorchidism. Sonographic appearances mirror the uniform cellular nature of the tumour; uniformly of low reflectivity although larger tumours may be heterogeneous, lobulated or present as multi-nodular areas in continuity (Figure 34). These tumours are particularly radiosensitive.

Figure 34 Seminoma. A low reflective mass (arrow) lying within testicular parenchyma, with a

well delineated border demonstrating features of a seminoma.



Non seminomatous germ cell tumours

The non-seminomatous germ cell tumours, a collective group of various cell types, affect the younger patient than seminomatous germ cell tumours and are more aggressive.

Mixed Germ Cell Tumours - Mixed germ cell tumour contains more than one germ cell component; any combination of cell type can occur. The most common combination is a teratoma and embryonal cell carcinoma often termed teratocarcinoma. These tumours are more common than the pure histological forms of testicular tumours. With ultrasonography the appearances reflect the diverse nature of the histology with areas of calcification, cystic change, haemorrhage and necrosis (Figure 35).

Embryonal Cell Carcinoma - Embryonal carcinoma is present in nearly all of mixed germ cell tumours, but in the pure form accounts for 2% of all testicular tumours. Embryonal carcinoma affects younger men and tends to be more aggressive, a significant number will present with metastases. These tumours are often heterogeneous, ill-defined and blending imperceptibly into adjacent testicular parenchyma (Figure 36).

Choriocarcinoma - Choriocarcinoma is a rare tumour in the pure form, occurring more often in a mixed germ cell tumour where it is highly malignant. Choriocarcinoma carries the worse prognosis of any germ cell tumour; a high level of human chorionic gonadotropin confers a poor prognosis. Sonography will demonstrate a heterogeneous solid mass with areas of haemorrhage, necrosis and calcification.

Yolk Sac Tumour - Yolk sac tumours are the infantile form of embryonal cell carcinoma and account for most of childhood (<2 years) tumours. This tumour is rare in adults except as a component of mixed germ cell tumours with elevation of α -fetoprotein levels often present. The sonographic features are non-specific and are similar to a mixed germ cell tumour with cystic change and areas of calcification.

Teratoma - Teratoma may be divided into mature, immature and teratoma with malignant transformation according to the presence of derivatives of the different germinal layers (endoderm, mesoderm and ectoderm). Teratoma is the second most common testicular tumour in children (<4 years), and teratoma cells occur in over 50% of adult cases of mixed germ cell tumours. A teratoma tends to be a complex tumour, and the sonographic features are those of a well-defined complex mass with calcification and cystic change (Figure 37). Malignant transformation into a teratocarcinoma is documented. In the pre-pubertal testes a pure teratoma is considered benign and testis-sparing surgery may be undertaken, but this is not the case for the post-pubertal teratoma which will metastasize irrespective of the histological features.

‘Regressed’ or ‘Burnt-out’ Germ Cell Tumours - Widespread germ cell metastases but no primary tumour except for an area of calcification or fibrosis within an often atrophic testis may be encountered (91). The pathogenesis of this phenomenon may be the result of a high metabolic rate of the tumour, which outgrows its blood supply and involutes (92;93).

Figure 35 Mixed Germ Cell Tumour. A focal mass (arrow), a mixed germ cell tumour, is present at the upper aspect of the testis, heterogeneous but mainly high reflectivity and is not as clearly defined as a seminoma.

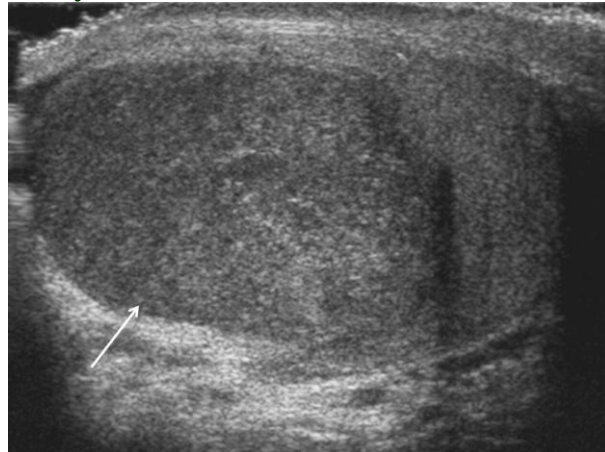


Figure 36 Embryonal cell tumour. Often a component of mixed germ cell tumours, this is an example of a pure embryonal cell tumour which is ill-defined and lobulated (arrow).

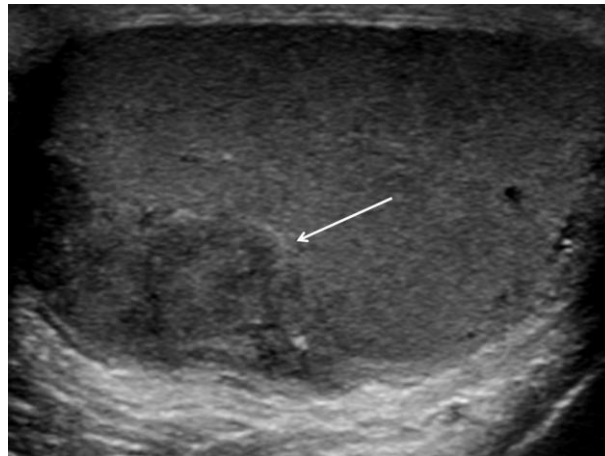
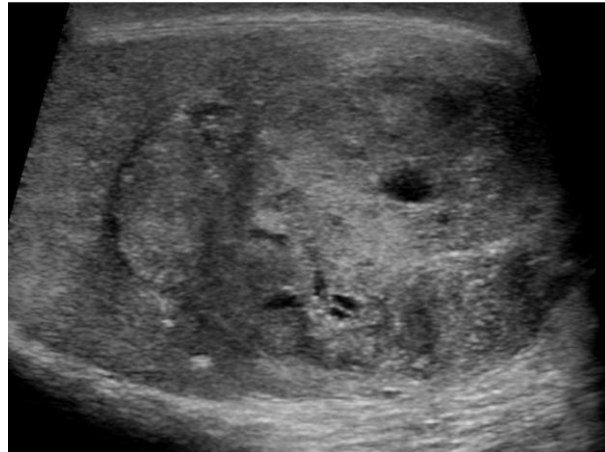

Figure 37 Teratoma. A large teratoma occupying the entire testis, demonstrating pockets of cystic change.



Non-germ cell tumours

Non-germ cell tumours (gonadal stromal tumours) account for 3-6% of all testicular tumours with a higher prevalence in the paediatric age group. Nearly all non-germ cell tumours are benign (90%), with no clear sonographic appearance that allows differentiation from malignant testicular tumours. These non-germ cell tumours contain Leydig, Sertoli, thecal, granulosa or lutein cells and fibroblasts. When combined with germ cell tumours are called gonadoblastomas.

Leydig Cell Tumours - The majority of non-germ cell tumours are Leydig cell tumours, which occur across all age groups, but the most common tumour found incidentally in infertile men (94). Patients demonstrate symptoms related to androgen or oestrogen secretion by the tumour which includes precocious virilization, gynaecomastia or decreased libido. On sonography Leydig cell tumours are small, low reflective with cystic change (95). Colour Doppler ultrasound may demonstrate poor internal vascularization with increased peripheral vascularity when small. Internal vascularity increases with tumour size (Figure 38) (96).

Sertoli Cell Tumours - Sertoli cell tumours are less likely than Leydig cell tumours to secrete hormones. On sonography Sertoli cell tumours are well-circumscribed, round and lobulated (Figure 39).

Lymphoma - It is unusual to develop testicular disease in lymphoma, only 0.3% of patients with lymphoma have testicular involvement (97), but testicular lymphoma may be the primary site of involvement, the initial manifestation of widespread disease or the site of recurrence. Testicular lymphoma is the most common testicular tumour in the over 60 year old age group, the most common secondary tumour of the testis and is the most common bilateral tumour. The most frequent type of lymphoma to affect the testis is non-Hodgkin's lymphoma, with sonographic appearances similar to germ cell tumours particularly a seminoma. Complete testicular involvement may be seen, emphasising the need to compare the reflectivity of both testes (Figure 40) (98).

Leukaemia - Primary leukaemia of the testis is rare, although a common site of recurrence in children (99). The blood-testis barrier prevents chemotherapy agents from dealing with intra-testicular leukaemia cells. The sonographic appearances are variable, being unilateral or bilateral, diffuse or focal, low or high reflective with increased colour Doppler flow (Figure 41) (100). Differentiation from inflammatory disease is difficult without a full clinical history.

Metastasis - Metastasis to the testis is unusual, with the most frequent primary sites being the prostate, lung, melanoma, colon and kidney (101). Metastases occur most commonly in patients over 50 years of age and usually in advanced disease. Metastases are indistinguishable on ultrasonography from primary tumours of the testis.

Figure 38 Leydig Cell Tumour. A large mixed reflective, heterogeneous tumour at the upper aspect of the testis which on histological examination was found to be a Leydig cell tumour.

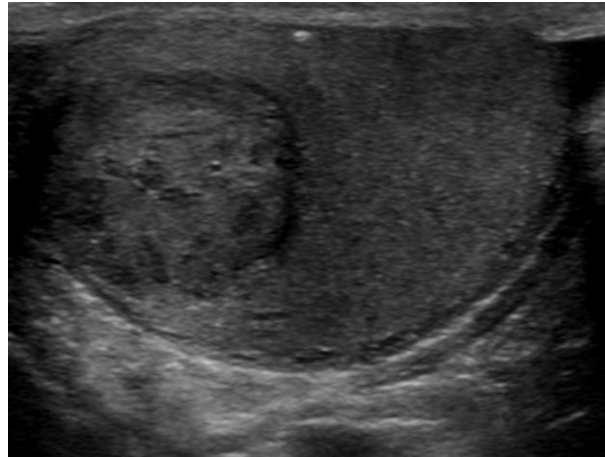


Figure 39 Sertoli Cell Tumour. This well circumscribed Sertoli cell tumour has linear wall calcification.

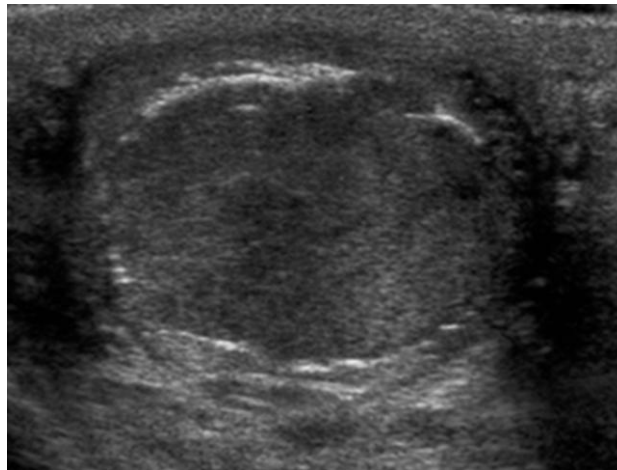
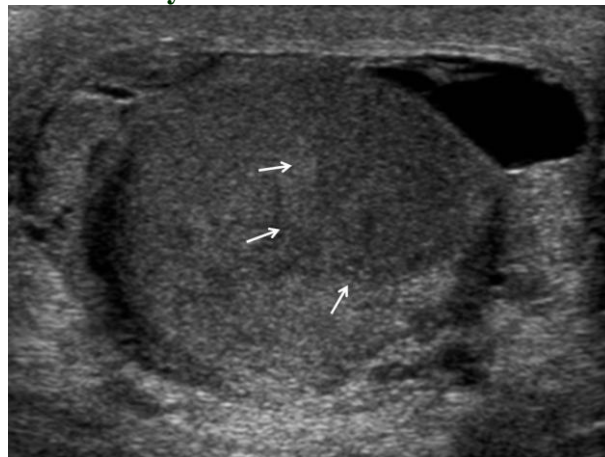


Figure 40 Lymphoma. There is enlargement of the testis, with a mass of uniform low reflective appearance (arrows). A surrounding hydrocele is present in a patient with testicular lymphoma.

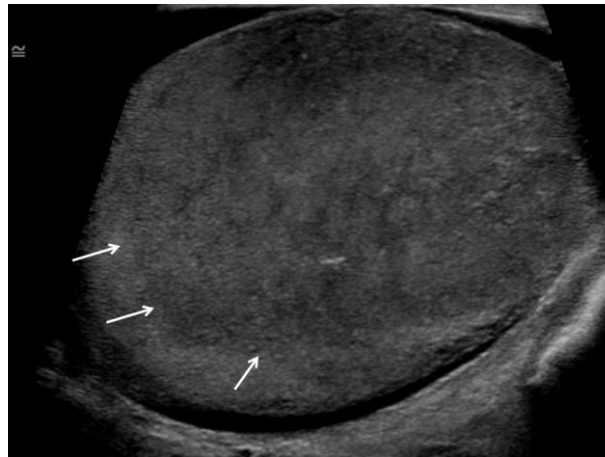

Figure 41 Leukaemia. An area of lower reflectivity (arrows) in a patient with acute myeloid leukaemia, with a small hydrocele.



Extra-testicular masses

Epididymal focal lesions

Extra-testicular solid tumours are uncommon; the majority of extra-testicular lesions are cystic abnormalities of the epididymis. Primary solid tumours of the extra-testicular tissues are normally benign except in children where a rhabdomyosarcoma is a possibility. Rarely metastases may also occur in the extra-testicular space.

Epididymal Cysts and Spermatocoeles - Extra-testicular cysts are found in the spermatic cord, epididymis (Figure 42), tunica albuginea or tunica vaginalis. Epididymal cysts are most commonly found in the epididymal head, contain clear serous fluid and on sonography demonstrate features typical of a cyst; anechoic structure with posterior acoustic enhancement. A spermatocoele consists of cystic dilatation of tubules of efferent ductules and occurs in the epididymal head (Figure 43), often containing low reflective debris representing spermatozoa, lymphocytes, cellular debris fat and proteinaceous fluid (102). The differentiation between a spermatocoele and a simple cyst is unimportant often indistinguishable on sonography. A spermatocoele is more common than an

epididymal cyst and more frequent in the epididymal head. An epididymal cyst may be large and simulate a hydrocoele; differentiation is usually attained by demonstrating fluid anterior to the testis in a hydrocoele.

Tubular Ectasia and Vasectomy - Following vasectomy, the epididymis has a characteristic appearance of dilatation, with an inhomogeneous appearance of the epididymis which are unrelated to symptoms and seen in over 45% of patients (Figure 44) (103).

Sperm Granuloma - A sperm granuloma is a granulomatous reaction to extra-vasated sperm cells and may occur secondary to inflammation, trauma or vasectomy. On sonography a sperm granuloma is well demarcated, of low or high reflectivity, without colour Doppler flow and normally found in the epididymis, (Figure 45) and often painful in the early stages (104).

Lipoma - This is the most common benign tumour of the extra-testicular space commonly found in the spermatic cord (105). Patients of all ages are affected, with the tumour manifesting as a non-tender scrotal lump. On sonography a lipoma has a homogenous high to iso-reflective appearance, and varies in size (Figure 46).

Adenomatoid Tumour - This is the most common tumour of the epididymis probably of a mesothelial origin. Adenomatoid tumours usually occur in the patient of 20 years or older, present as a painless mass, slow growing, arise in the tail of the epididymis and are predominantly left sided (106). The sonographic appearance is non-specific; the majority are iso-reflective to the epididymis, well defined, oval in shape and may be cystic (Figure 47) (107). Resection is normally curable, but will interfere with sperm ejaculation on the side of the resection.

Leiomyoma - This is the second commonest tumour of the epididymis, commonly involving the epididymal head and is often associated with a hydrocele. The patient presents with a slow-growing non-tender mass. On sonography there are no specific features, may be cystic or solid and contain areas of calcification (108).

Other rare benign tumours of the extra-testicular space -Haemangiomas (Figure 48) (109), which may be indistinguishable from a varicocele, a papillary cystadenoma associated with von Hippel-Lindau disease, appearing as a solid lesion with small cystic spaces in the head of the epididymis (110). A fibrous pseudotumour (Figure 49) may result from a prior history of trauma, haematocoele or from epididymo-orchitis (111)

Malignant Neoplasms - Malignant lesions of the extra-testicular space are rare, usually present as a mildly painful enlarging mass, and the vast majority are sarcomas (106). A **rhabdomyosarcoma** is the most common sarcoma of the spermatic cord and presents as an enlarging painless mass in a child. This is an aggressive tumour which may present with metastases. Sonographic features are non-specific; variable reflectivity with areas of necrosis and haemorrhage and increased colour Doppler flow (112). A **liposarcoma** is very rare and usually arises from the spermatic cord, is of low-grade malignancy, advancing by local spread with patients presenting with a slow-growing fluctuant mass. Sonography demonstrates a high reflective mass of varying size. Other rare malignant lesions of the extra-testicular space include **leiomyosarcoma** which is seen as a predominantly low reflective mass (113), **malignant schwannoma** and malignant **fibrous histiocytoma**. A **mesothelioma** may develop from the tunica vaginalis in patients exposed to asbestos (114). Lastly, metastases to the extra-testicular space occur from a testicular primary tumour, renal, prostate and gastrointestinal tumours.

Figure 42 Epididymal Head Cyst. A large epididymal head cyst (star) displaces the testis inferiorly. An additional feature is a thickened epididymal body (arrow).

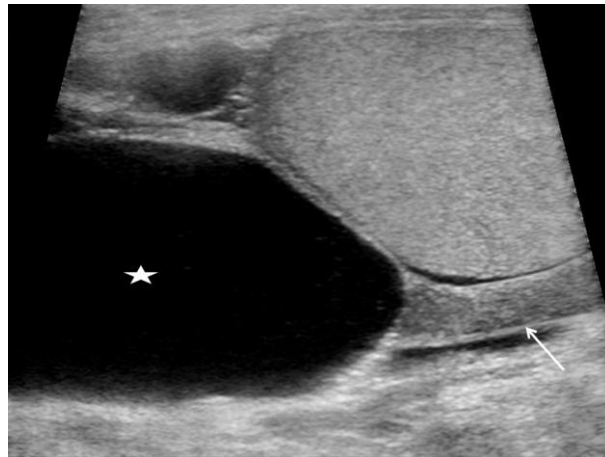


Figure 43 Spermatocele. Two cysts in the epididymal head demonstrates debris (arrows) that is 'layering'; a spermatocele..

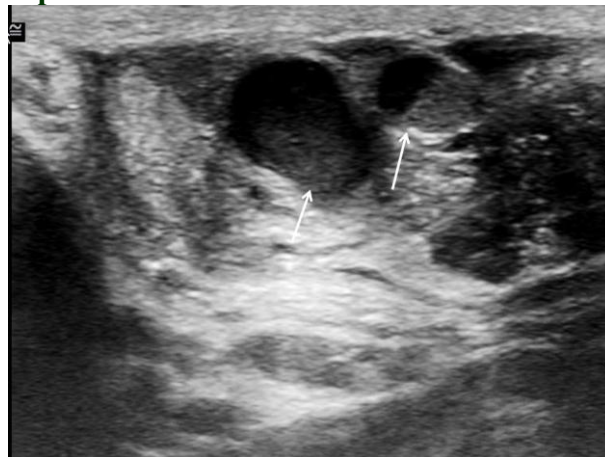

Figure 44 Post-vasectomy. The epididymis is dilated (between arrows) in a patient who has undergone a vasectomy, with a characteristic reflective pattern demonstrated.

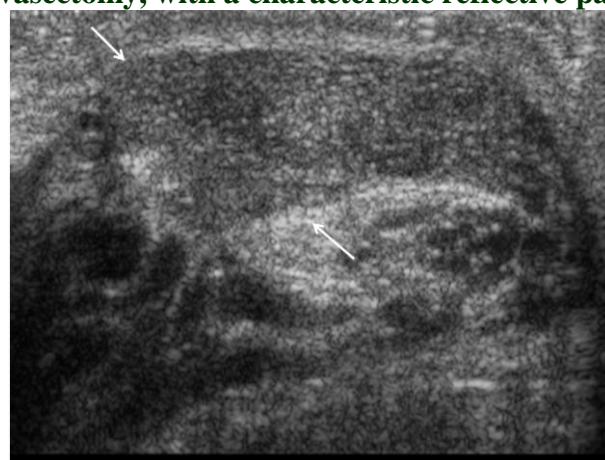

Figure 45 Sperm Granuloma. A focal low reflective lesion in the epididymis (arrow) which is painful; a sperm granuloma on histology.

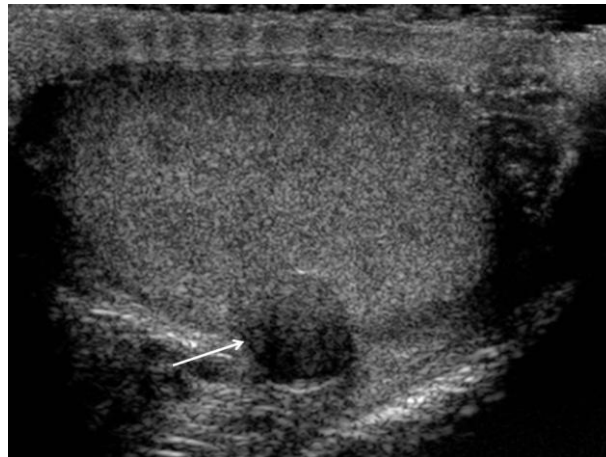

Figure 46 Lipoma. A focal mixed reflective extra-testicular lesion (arrow) in keeping with a lipoma lying at the lower aspect inferior to the testis (star).

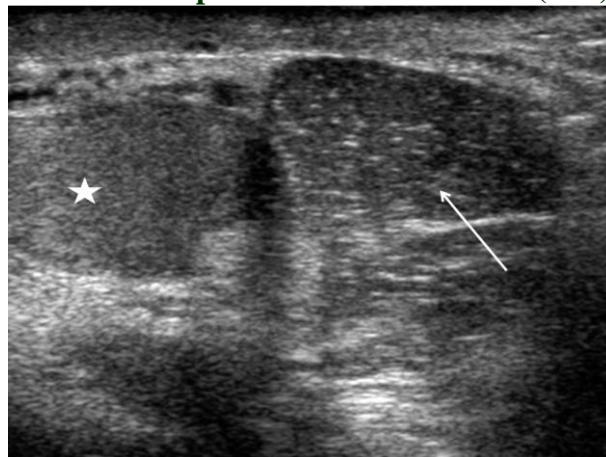


Figure 47 Adenomatoid Tumour. A large mixed reflective mass (arrow) present in the tail of the epididymis; an adenomatoid lesion on histology.

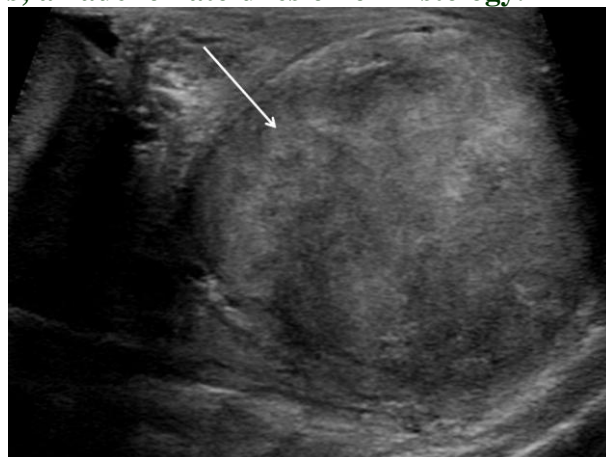

Figure 48 Cavernous Haemangioma of the Spermatic Cord. A well circumscribed lesion of the spermatic cord containing pockets of increased colour Doppler flow (long arrow); a cavernous haemangioma

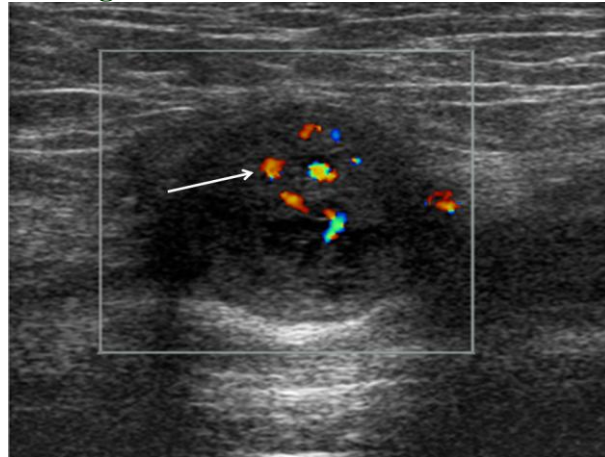
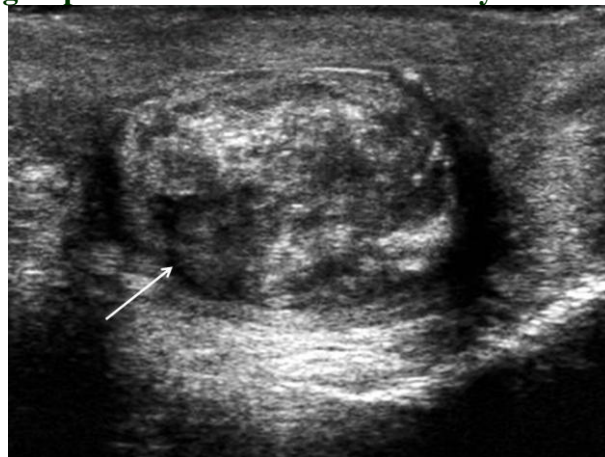


Figure 49 Fibrous Pseudotumour. A fibrous pseudo-tumour of the epididymal tail (arrow) demonstrating a spectrum of different reflectivity.



Scrotal calcification

Testicular microlithiasis and macrocalcification

Testicular microlithiasis describes the appearance of multiple tiny bright foci, measuring 1-2mm in diameter, which may be unilateral or bilateral (Figure 50). Acoustic shadowing is not seen, probably due to the small size of the calcifications. Testicular microlithiasis has been arbitrarily classified into “limited” defined as less than 5 microliths per ultrasound field, “classical” defined as greater than 5 microliths per field (115). A further definition, “florid”, where there are innumerable microliths per ultrasound field has also been suggested (116). The prevalence of all forms of testicular microlithiasis is reported at 0.6% to 9.0% (117;118). Testicular microlithiasis is characterized by the formation of microliths from degenerating cells in the seminiferous tubules. Testicular microlithiasis has been associated with various medical conditions, including infertility, cryptorchidism, Klinefelters syndrome, Down's syndrome and pulmonary alveolar microlithiasis (119). Testicular microlithiasis has also been found in association with malignant tumours in the

testis with seminoma the commonest tumour to occur in association with testicular microlithiasis (Figure 51) (120). As a consequence the significance of finding isolated testicular microlithiasis is as yet uncertain; surveillance with ultrasonography on an annual basis is advocated (117). A number of case reports have detailed the development of a primary testicular tumour whilst on an ultrasound surveillance program (118;121).

The association of testicular macrocalcification within benign testicular lesions is well documented and can be found in association with intra-testicular cysts and epidermoid tumours. Large smooth curvilinear calcification at the periphery of a tissue mass has been shown in Sertoli cell tumours. Granulomatous disease within the testes can also present with a low reflective mass and areas of calcification within (122). The presence of macrocalcification in association with malignant tumours has also been raised; particular with the entity of 'burnt-out' tumours, and recently macrocalcification has been associated with a higher prevalence of primary testicular tumours (Figure 52) (123).

Figure 50 Testicular Microlithiasis. Rightsided classical testicular microlithiasis; small high reflective areas measuring 1-2mm without evidence of posterior acoustic shadowing.

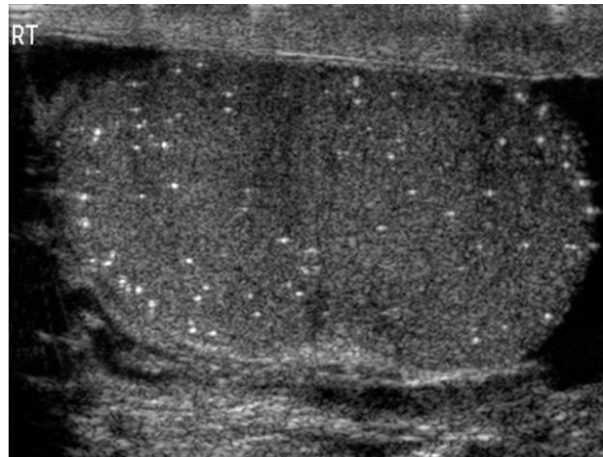


Figure 51 Seminoma with Testicular Microlithiasis. Testicular microlithiasis (short arrows) in association with a bi-lobulated seminoma (long arrows). There is an increased prevalence of primary testicular tumours in the presence of testicular microlithiasis.

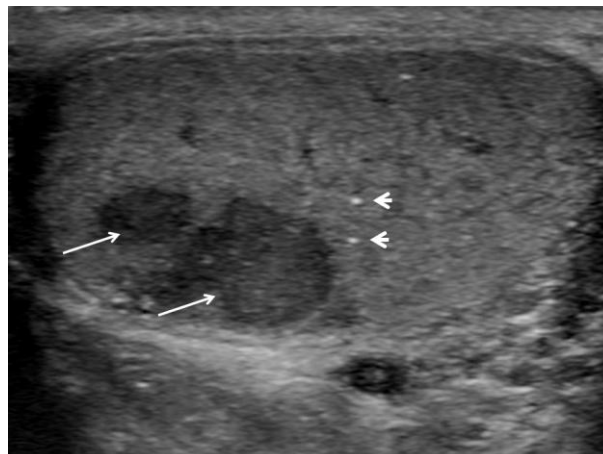
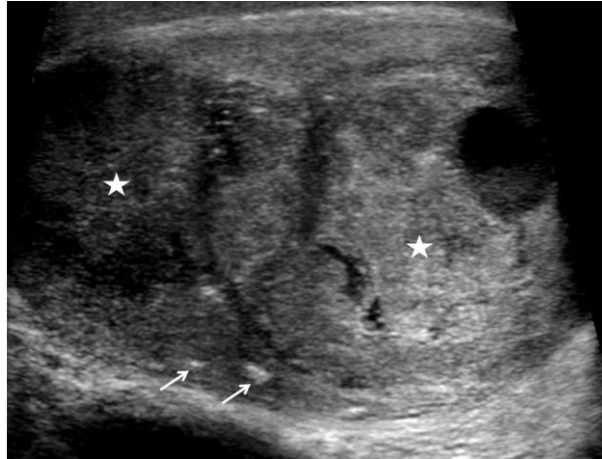


Figure 52 Tumours with Testicular Macrocalcification. Two germ cellin tumours are present (stars) the testis, with focal areas of macro calcification lying outside the tumour margins (arrows).



Extra-testicular calcification

Calcification within the epididymis is common and represents benign disease (124). The tunica vaginalis may sometimes calcify producing a plaque with acoustic shadowing as will calcification in the tunica albuginea (Figure 53). Calcification in the epididymis is usually due to chronic epididymitis. Haematoma and sperm granulomas (sperm extravasation with granuloma formation) may occur and produce a solitary high reflective area within the epididymis. The appendix epididymis and appendix testis may calcify and are recognized by their characteristic position and shape (122). Calcifications present in between the two layers of the tunica vaginalis are termed 'scrotal pearls', best appreciated in the presence of a hydrocele (Figure 54). A scrotal pearl, often palpated by the patient, is usually freely mobile within a hydrocele.

Figure 53 Tunica Albuginea Calcification. A focus of high reflectivity in the tunica albuginea (arrow) causing extensive posterior acoustic shadowing.

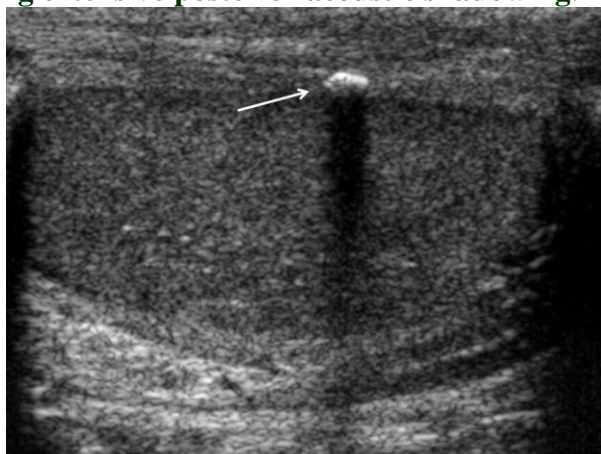
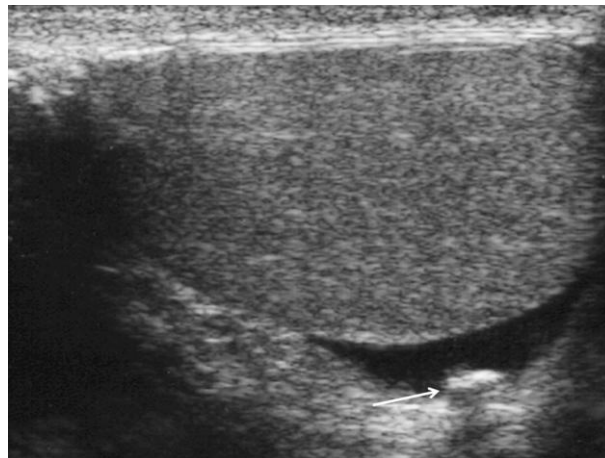

Figure 54 Scrotal Pearl. The high reflective area (arrow) lying free within a small hydrocele within the scrotal sac represents a 'scrotal pearl', and cause posterior acoustic shadowing.



Extra-testicular non-focal lesions

Inguinal Hernia - Inguinal hernias are a common cause of a scrotal swelling with a physical examination sufficient to arrive at the correct diagnosis but sonography may be useful in the difficult case. On sonography the hernia contains bowel or omentum giving rise to peristalsis of fluid filled loops of bowel, air within bowel or high reflective omental fat (Figure 55).

Hydrocele, pyocele and haematocele - Between the two layers of the tunica vaginalis, there is normally a small amount of serous fluid present, visualised in up to 85% of asymptomatic men (9). When the collection of fluid enlarges, a hydrocele develops; the commonest cause of a painless scrotal swelling. The fluid accumulation is confined to the anterior and lateral aspects scrotum sparing the bare area of the testis. A hydrocele is normally of low reflectivity, with posterior acoustic enhancement but may contain multiple echoes in the presence of cholesterol crystals (Figure 56) (125). Hydroceles may be idiopathic or develop secondary to trauma (haematocele), infection (pyocele), torsion, tumour or congenital (secondary to a patent processus vaginalis). The testis is normally displaced to the posterior aspect of the scrotal sac in the presence of a hydrocele, in contrast to the inferior position when a large epididymal cyst causes displacement of the testis.

Varicocele - A varicocele is present in up to 15% of adult male patients (126), caused by incompetent valves in the internal spermatic vein. Impaired drainage is more evident when standing upright or during a Valsalva manoeuvre which renders the varicocele more prominent. Varicoceles are left sided in 78%, right sided in 6% and bilateral in 15%. This abnormal dilatation of veins arises more often on the left as a consequence of the angle at which the left testicular vein enters the left renal vein. The normal veins of the pampiniform plexus measure 0.5 to 1.5mm and a vein diameter of greater than 2mm should be considered abnormal (127). On sonography, a varicocele consists of multiple low reflective serpiginous tubular structures of varying size, best seen superior and lateral to the testis. If large the varicocele may extend to the inferior aspect of the testis (Figure 57). Tumbling low-level echoes may be identified on real time imaging, secondary to low flow. Sonography in the supine and erect positions as well as following the Valsalva maneuver will help identify the varicocele and document retrograde filling. Examination of the left kidney is advocated in the presence of a varicocele to exclude a renal tumour in all patients by many clinicians, without much supporting evidence as to the prevalence of this association (128). This is probably only really indicated in the presence of a varicocele that has recently arisen in patients over the age of 40 years.

Occasionally an intra-testicular varicocele may occur (Figure 58) (129;130). The appearance on colour and spectral Doppler examination is characteristic, as an intra-testicular varicocele demonstrates vascular flow. An intra-testicular varicocele will behave in a similar fashion to an extra-testicular varicocele, increasing in size and demonstrating retrograde flow on Valsalva manoeuvre. A common clinical presentation is with testicular pain attributed to stretching of the tunica albuginea secondary to venous congestion (131).

A classification of varicoceles based on clinical features is as follows; Grade 1, varicocele is palpable only during the Valsalva manoeuvre, Grade 2, readily palpable without the need for the Valsalva manoeuvre and Grade 3, visible on inspection (132). Identification of a varicocele in patients being investigated for infertility may be of relevance, although testicular volume, sonographic appearances and Doppler studies may also be of importance (133).

Figure 55 Inguinal hernia. The left scrotal sac contains high reflective omentum (arrow) from an inguinal hernia on this spectacle view of the scrotal contents.

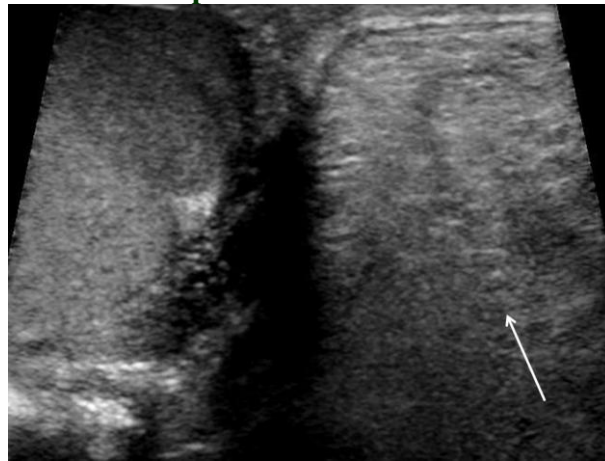


Figure 56 Extra-testicular Fluid Collection. Extensive high reflective material within a chronic hydrocele representing cholesterol crystals, with the testis at the lower aspect (star).

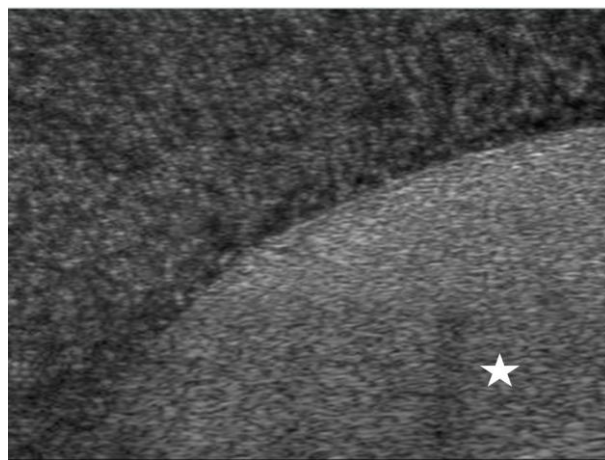


Figure 57 Extra-testicular Varicocele. Serpiginous dilated (>2mm) veins at the lower aspect of

the testis; a testicular varicocele (arrow).

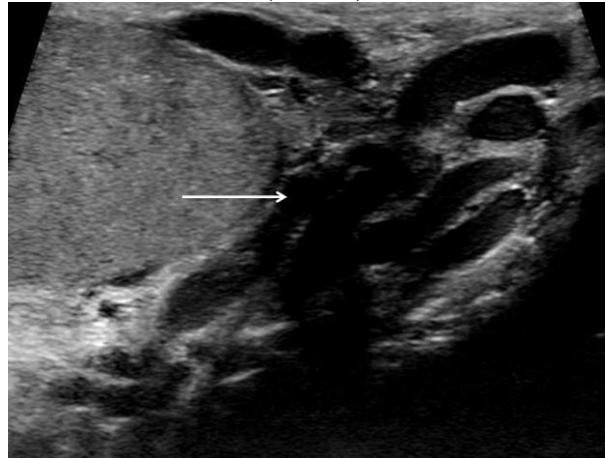
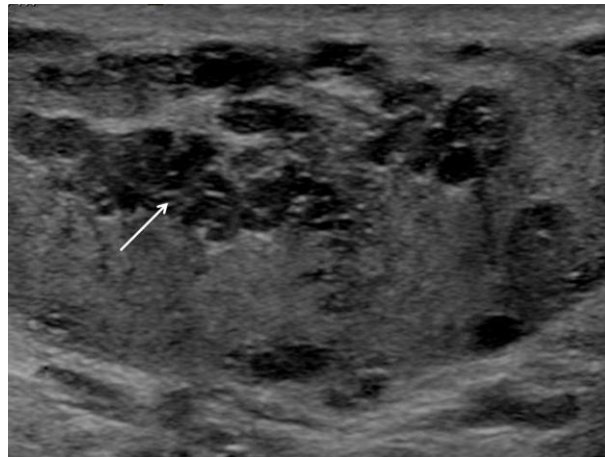


Figure 58 Intra-testicular Varicocele. A dilated intra-testicular tubular structure (arrow) traversing the testis.



Scrotal wall abnormalities

Scrotal wall oedema may occur in many conditions; heart failure, liver failure, lymphatic obstruction and venous obstruction. Lymph oedema of the scrotal wall is classical described in filarial worm infestations (134). Testicular oedema results in fluid tracking into the interstitial tissues of the testis as a consequence of marked subcutaneous oedema of the scrotal sac. This gives rise to low reflective linear branching throughout the testes giving a ‘crazy paving’ appearance (135). The linear branching low reflective areas demonstrate no colour Doppler signal.

References

- (1) Langman J. Genital System. Medical Embryology. 3rd ed. Baltimore: Williams and Wilkins; 1975. p. 175-200.

- (2) Aziz ZA, Satchithananda K, Khan M, Sidhu PS. High-frequency color Doppler ultrasonography of the spermatic cord arteries: resistive index variation in a cohort of 51 healthy men. *J Ultrasound Med* 2005;24:905-9.
- (3) Paltiel HJ, Diamond DA, Di Canzio J, Zurakowski D, Borer JG, Atala A. Testicular volume: comparison of orchidometer and US measurements in dogs. *Radiology* 2002;222:114-9.
- (4) Ingram S, Hollman AS. Colour Doppler sonography of the normal paediatric testis. *Clin Radiol* 1994;49:266-7.
- (5) Sellars MEK, Sidhu PS. Pictorial review: ultrasound appearances of the rete testis. *Eur J Ultrasound* 2001;14:115-20.
- (6) Sellars MEK, Sidhu PS. Ultrasound appearances of the testicular appendages: pictorial review. *Eur Radiol* 2003;13:127-35.
- (7) Keener TS, Winter TC, Nghiem HV, Schmiedl UP. Normal adult epididymis: evaluation with color Doppler ultrasound. *Radiology* 1997;202:712-4.
- (8) Rolnick D, Kawanoue S, Szanto P, Bush IM. Anatomical incidence of testicular appendages. *J Urology* 1968;100:755-6.
- (9) Leung ML, Gooding GAW, Williams RD. High-resolution sonography of scrotal contents in asymptomatic subjects. *AJR Am J Roentgenol* 1984;143:161-4.
- (10) Middleton WD, Meredith MW. Analysis of intratesticular arterial anatomy with emphasis on transmediastinal arteries. *Radiology* 1993;189:157-60.
- (11) Nicolaou S, Cooperberg PL. The two-tone testis due to refractive shadowing of the intratesticular artery. *J Ultrasound Med* 1995;14:963-5.
- (12) Bushby LH, Sellars ME, Sidhu PS. The "two-tone" testis: spectrum of ultrasound appearances. *Clin Radiol* 2007;62:1119-23.
- (13) Johnson KA, Dewbury KC. Ultrasound imaging of the appendix testis and appendix epididymis. *Clin Radiol* 1996;51:335-7.
- (14) Strauss S, Faingold R, Manor H. Torsion of the testicular appendages: sonographic appearance. *J Ultrasound Med* 1997;16:189-92.
- (15) Rifkin MD, Kurtz AB, Pasto ME, Goldberg BB. Polyorchidism diagnosed preoperatively by ultrasonography. *J Ultrasound Med* 1983;2:93-4.
- (16) Amodio JB, Maybody M, Slowotsky C, Fried K, Foresto C. Polyorchidism: Report of 3 Cases and Review of the Literature. *J Ultrasound Med* 2004;23:951-7.
- (17) Singer BR, Donaldson JG, Jackson DS. Polyorchidism: functional classification and management strategy. *Urology* 1992;39:384-8.
- (18) Leung AK. Polyorchidism. *Am Fam Physician* 1988;38:153-6.

- (19) Chung TJ, Yao WJ. Sonographic features of polyorchidism. *J Clin Ultrasound* 2002;30:106-8.
- (20) Rajbabu K, Morel JC, Thompson PM, Sidhu PS. Multi-cystic (rete testis) supernumerary testis in polyorchidism with underlying microlithiasis: ultrasound appearances. *Aust Radiol* 2007;5s1:B56-B58.
- (21) Mathur P, Prabhu K, Khamesra HL. Polyorchidism revisited. *Pediatric Surg Int* 2002;18:449-50.
- (22) Grechi G, Zampi GC, Selli C, Carini SM, Ucci M. Polyorchidism and seminoma in a child. *J Urol* 1980;123:291-2.
- (23) Siegal A, Snyder H, Duckett JW. Epididymitis in infants and boys: underlying anomalies and efficacy of imaging modalities. *J Urology* 1987;138:1100-3.
- (24) Horstman WG, Middleton WD, Melson GL. Scrotal inflammatory disease: Color Doppler US findings. *Radiology* 1991;179:55-9.
- (25) Fitzgerald SW, Erickson SJ, Dewire DM, Foley WD, Lawson TL, Begun FP, et al. Color sonography in the evaluation of the adult acute scrotum. *J Ultrasound Med* 1992;11:543-8.
- (26) Cook JL, Dewbury K. The changes seen on high-resolution ultrasound in orchitis. *Clin Radiol* 2000;55:13-8.
- (27) Amaechi I, Sidhu PS. Ultrasound in the assessment of the "on-call" acute scrotum. *Imaging* 2008;20:131-8.
- (28) Rencken RK, DuPlessis DJ, DeHaas LS. Venous infarction of the testes - a cause of non-response to conservative therapy in epididymo-orchitis: a case report. *South African Med J* 1990;78:337-8.
- (29) Bird K, Rosenfield AT. Testicular infarction secondary to acute inflammatory disease: demonstration by B-scan ultrasound. *Radiology* 1984;152:785-8.
- (30) Yang DM, Yoon MH, Kim HS, Jin W, Hwang HY, Kim HS, et al. Comparison of tuberculous and pyogenic epididymal abscesses: clinical, gray-scale sonographic and color Doppler sonographic features. *Am J Roentgenol* 2001;177:1131-5.
- (31) Kim SH, Pollack HM, Cho KS, Pollack MS, Han MC. Tuberculous epididymitis and epididymo-orchitis: sonographic findings. *J Urol* 1993;150:80-4.
- (32) Drudi FM, Laghi A, Iannicelli E, Di Nardo R, Occhiato R, Poggi R, et al. Tubercular epididymitis and orchitis: US patterns. *Eur J Radiol* 1997;7:1076-8.
- (33) Dogra VS, Bhatt S. Acute painful scrotum. *Radiol Clin North Am* 2004;42:349-63.
- (34) Lentini JF, Benson CB, Richie JP. Sonographic features of focal orchitis. *J Ultrasound Med* 1989;8:361-5.
- (35) Bhandary P, Abbit PL, Watson L. Ultrasound diagnosis of traumatic testicular rupture. *J Clin Ultrasound* 1992;20:346-8.

- (36) Herbener TE. Ultrasound in the assessment of the acute scrotum. *J Clin Ultrasound* 1996;24:405-21.
- (37) Muschat M. The pathological anatomy of testicular torsion: explanation of its mechanism. *Surg Gynaecol Obst* 1932;54:758-63.
- (38) Corrsiere JN. Horizontal lie of the testicle: a diagnostic sign and torsion of the testis. *J Urology* 1972;107:616-7.
- (39) Blackhouse KM. Embryology of testicular descent and maldescent. *Urol Clin North Am* 1982;9:315.
- (40) Zafaranolo S, Gerard PS, Wise G. Bilateral neonatal testicular torsion: ultrasonographic evaluation. *J Urology* 1986;135:589-90.
- (41) Luker GD, Siegel MJ. Color Doppler sonography of the scrotum in children. *Am J Roentgenol* 1994;163:649-55.
- (42) Williamson RCN. Torsion of the testis and allied conditions. *Br J Surg* 1976;63:465-76.
- (43) Cass AS, Cass BP, Veeraraghawan K. Immediate exploration of the unilateral acute scrotum in young male subjects. *J Urology* 1980;124:829-32.
- (44) Hricak H, Lue TF, Filly RA, Alpers CE, Zeineh SJ, Tanagho EA. Experimental study of the sonographic diagnosis of testicular torsion. *J Ultrasound Med* 1983;2:349-56.
- (45) van Dijk R, Karthaus HFM. Ultrasonography of the spermatic cord in testicular torsion. *Eur J Radiol* 1994;18:220-3.
- (46) Vijayaraghavan SB. Sonographic Differential Diagnosis of Acute Scrotum: Real-time Whirlpool Sign, a Key Sign of Torsion. *J Ultrasound Med* 2006;25:563-74.
- (47) Lerner RG, Mevorach RA, Hulbert WC, Rabinowitz R. Color Doppler US in the evaluation of acute scrotal disease. *Radiology* 1990;176:355-8.
- (48) Eisner DJ, Goldman SM, Petronis J, Millmond SH. Bilateral testicular infarction caused by epididymitis. *AJR Am J Roentgenol* 1991;157:517-9.
- (49) Dogra VS, Rubens DJ, Gottlieb RH, Bhatt S. Torsion and Beyond: New Twists in Spectral Doppler Evaluation of the Scrotum. *J Ultrasound Med* 2004;23:1077-85.
- (50) Sanders LM, Haber S, Dembner A, Aquino A. Significance of reversal of diastolic flow in the acute scrotum. *J Ultrasound Med* 1994;13:137-9.
- (51) Sidhu PS. Clinical and imaging features of testicular torsion: role of ultrasound. *Clin Radiol* 1999;54:343-52.
- (52) McCombe AW, Scobie WG. Torsion of scrotal contents in children. *Br J Urol* 1988;61:148-50.
- (53) Stamenkovic I, Lew PD. Early recognition of potentially fatal necrotizing fasciitis. The use of frozen-section biopsy. *N Engl J Med* 1984;28:1689-93.

- (54) Clayton MD, Fowler JE, Sharifi R, Pearl RK. Causes, presentation and survival of 57 patients with necrotising fasciitis of the male genitalia. *Surg Gynaecol Obstet* 1990;170:49-55.
- (55) Paty R, Smith AD. Gangrene and Fournier's gangrene. *Urol Clin North Am* 1992;19:149-62.
- (56) Kane CJ, Nash P, McAninch JW. Ultrasonographic appearance of necrotizing gangrene: aid in early diagnosis. *Urology* 1996;48:142-4.
- (57) Rajan DK, Scharer A. Radiology of Fournier's gangrene. *AJR Am J Roentgenol* 1998;170:163-8.
- (58) Atchley JTM, Dewbury KC. Ultrasound appearances of testicular epidermoid cysts. *Clin Radiol* 2000;55:493-502.
- (59) Shapeero LG, Vordermark JS. Epidermoid cysts of testes and role of sonography. *Urology* 1993;41:75-9.
- (60) Seidenwurm D, Smathers RL, Kan P, Hoffman A. Intratesticular adrenal rests diagnosed by ultrasound. *Radiology* 1985;155:479-81.
- (61) Avila NA, Premkumar A, Shawker TH, Jones JV, Laue L, Cutler GB. Testicular adrenal rest tissue in congenital adrenal hyperplasia: findings at gray-scale and color Doppler US. *Radiology* 1996;198:99-104.
- (62) Costa M, Calleja R, Ball RY, Burgess N. Segmental testicular infarction. *Br J Urol International* 1999;83:525.
- (63) Fernandez-Perez GC, Tardaguila FM, Velasco M, Rivas C, Dos Santos J, Cambronero J, et al. Radiologic Findings of Segmental Testicular Infarction. *Am J Roentgenol* 2005;184:1587-93.
- (64) Bilagi P, Sriprasad S, Clarke J, Sellars M, Muir G, Sidhu P. Clinical and ultrasound features of segmental testicular infarction: Six-year experience from a single centre. *Eur Radiol* 2007;17:2810-8.
- (65) Sriprasad SI, Kooiman GG, Muir GH, Sidhu PS. Acute segmental testicular infarction: differentiation from tumour using high frequency colour Doppler ultrasound. *Br J Radiol* 2001;74:965-7.
- (66) Carragher AM. One hundred years of splenogonadal fusion. *Urology* 1990;35:471-5.
- (67) Putschar WGJ, Manion WC. Splenic-gonadal fusion. *Am J Pathol* 1955;32:15-33.
- (68) Kalomenopoulou M, Katsimba D, Arvaniti M, Chakkas J, Sinopidis X, Kotakidou R, et al. Male splenic-gonadal fusion of the continuous type: sonographic findings. *Eur Radiol* 2002;12:374-7.
- (69) Henderson RG, Henderson DC, Reid IN, Atkinson PM. Case report: splenic-gonadal fusion. The ultrasound appearances. *Clin Radiol* 1991;44:117-8.

- (70) Stewart VR, Sellars ME, Somers S, Muir GH, Sidhu PS. Splenogonadal Fusion: B-Mode and Color Doppler Sonographic Appearances. *J Ultrasound Med* 2004;23:1087-90.
- (71) Astudillo L, Payoux P, Game X, Sailer L, Arne JL, Arlet-Suau E. Bilateral testicular and epididymal involvement in sarcoidosis. *Am J Med* 2004;116:646-7.
- (72) Rehman J, Rizkala ER, Chughtai B, Khan SA. Hypoechoic testicular mass: a case of testicular and epididymal sarcoidosis. *Urology* 2005;66:e9-e10.
- (73) Eraso CE, Vrachliotis TG, Cunningham JJ. Sonographic findings in testicular sarcoidosis simulating malignant nodule. *J Clin Ultrasound* 1999;27:81-3.
- (74) Ricker W, Clarke M. Sarcoidosis: a clinicopathological review of 300 cases including 22 autopsies. *Am J Clin Pathol* 1949;19:725.
- (75) Subramanyan BR, Horri SC, Hilton S. Diffuse testicular disease: sonographic features and significance. *AJR Am J Roentgenol* 1985;145:1221-4.
- (76) Mevorach RA, Lerner RM, Dvoretzky PM, Rabinowitz R. Testicular abscess: diagnosis by ultrasonography. *J Urol* 1986;136:1213-6.
- (77) Pavlica P, Barozzi L. Imaging of the acute scrotum. *Eur Radiol* 2001;11:220-8.
- (78) Megremis S, Michalakou M, Mattheakis M, Agianniotakis E, Sfakianaki E. An Unusual Well-Circumscribed Intratesticular Traumatic Hematoma: Diagnosis and Follow-up by Sonography. *J Ultrasound Med* 2005;24:547-50.
- (79) Purushothaman H, Sellars ME, Clarke JL, Sidhu PS. Intra-testicular haematoma: differentiation from tumour on clinical history and ultrasound appearances in two cases. *Br J Radiol* 2007;80:e184-e187.
- (80) Hamm B, Fobbe F, Loy V. Testicular cysts: differentiation with US and clinical findings. *Radiology* 1988;168:19-23.
- (81) Rouviere O, Bouvier R, Pangaud C, Jeune C, Dawahra M, Lyonnet D. Tubular ectasia of the rete testis: a potential pitfall in scrotal imaging. *Eur Radiol* 1999;9:1862-8.
- (82) Harris RD, Chouteau C, Patrick M, Schned A. Prevalence and significance of heterogeneous testes revealed on sonography: ex vivo sonographic-pathologic correlation. *Am J Roentgenol* 2000;175:347-52.
- (83) Greenlee RT, Hill-Harmon MB, Murray T, Thun M. Cancer Statistics, 2001. *CA Cancer J Clin* 2001;51:15-36.
- (84) Grantham JG, Charboneau JW, James EM, Kirschling RJ, Kvols LK, Segura JW, et al. Testicular neoplasms: 29 tumors studied by high-resolution US. *Radiology* 1985;157:775-80.
- (85) Horstman WG, Melson GL, Middleton WD, Andriole GL. Testicular tumours: Findings with color Doppler US. *Radiology* 1992;185:733-7.

- (86) Bushby LH, Sriprasad S, Hopster D, Muir G, Clarke JL, Sidhu PS. High frequency colour Doppler US of focal testicular lesions: crossing vessels (criss-cross pattern) identifies primary malignant tumours. *Radiology* 2001;221:449.
- (87) Sidhu PS, Sriprasad S, Bushby LH, Sellars ME, Muir GH. Impalpable testis cancer. *BJU International* 2004;93:888.
- (88) Woodward PJ, Schwab CM, Sesterhenn IA. Extratesticular Scrotal Masses: Radiologic-Pathologic Correlation. *Radiographics* 2003;23:215-40.
- (89) Heiken JP. Tumors of the testis and testicular adenexa. In: Pollack HM, McClellan BL, editors. *Clinical Urography*. 2nd ed. Philadelphia, PA: Saunders; 2000. p. 1716-41.
- (90) Mostofi FK, Sesterhenn IA, Davis CJ. Immunopathology of germ cell tumours of the testis. *Semin Diag Pathol* 1987;4:320-41.
- (91) Comiter CV, Renshaw AA, Benson CB, Loughlin KR. Burned-out primary testicular cancer: sonographic and pathological characteristics. *J Urol* 1996;156:85-8.
- (92) Balzer BL, Ulbright TM. Spontaneous regression of testicular germ cell tumours. Analysis of 42 cases. *Am J Surg Pathol* 2006;30:858-65.
- (93) Tasu JP, Faye N, Eschwege P, Rocher L, Blery M. Imaging of Burned-out Testis Tumor: Five New Cases and Review of the Literature. *J Ultrasound Med* 2003;22:515-21.
- (94) Carmignani L, Gadda F, Gazzano G, Nerva F, Mancini M, Ferruti M et al. High Incidence of Benign Testicular Neoplasms Diagnosed by Ultrasound. *J Urology* 2003;170:1783-6.
- (95) Avery GR, Peakman DJ, Young JR. Unusual hyperechoic ultrasound appearance of testicular Leydig cell tumour. *Clin Radiol* 1991;43:260-1.
- (96) Maizlin ZV, Belenky A, Kunichezky M, Sandbank J, Strauss S. Leydig Cell Tumors of the Testis: Gray Scale and Color Doppler Sonographic Appearance. *J Ultrasound Med* 2004;23:959-64.
- (97) Doll DC, Weiss RB. Malignant lymphoma of the testis. *Am J Med* 1986;81:515-23.
- (98) Mazzu D, Jeffrey RB, Ralls PW. Lymphoma and leukaemia involving the testicles: findings on gray-scale and color Doppler sonography. *AJR Am J Roentgenol* 1995;164:645-7.
- (99) Philips G, Kumari-Subaiya S, Swaitsky A. Ultrasonic evaluation of the scrotum in lymphoproliferative disease. *J Ultrasound Med* 1987;6:169-75.
- (100) Rayor RA, Scheible W, Brock WA, Leopold GR. High resolution ultrasonography in the diagnosis of testicular relapse in patients with acute lymphoblastic leukaemia. *J Urol* 1982;128:602-3.
- (101) Garcia-Gonzalez R, Pinto J, Val-Bernal JF. Testicular metastases from solid tumours: an autopsy study. *Ann Diagn Pathol* 2000;4:397-400.

- (102) Rifkin MD, Kurtz AB, Goldberg BB. Epididymis examined by ultrasound: correlation with pathology. *Radiology* 1984;151:187-90.
- (103) Jarvis LJ, Dubbins PA. Changes in the epididymis after vasectomy: sonographic findings. *AJR Am J Roentgenol* 1989;152:531-4.
- (104) Ramanathan K, Yaghoobian J, Pinck RL. Sperm granuloma. *J Clin Ultrasound* 1986;14:155-6.
- (105) Lioe TF, Biggart JD. Tumours of the spermatic cord and paratesticular tissue. A clinicopathological study. *Br J Urol* 1993;71:600-6.
- (106) Akbar SA, Sayyed TA, Jafri SZH, Hasteh F, Neill JSA. Multimodality Imaging of Paratesticular Neoplasms and Their Rare Mimics. *Radiographics* 2003;23:1461-76.
- (107) Makarainen HP, Tammela TL, Karttunen TJ, Mattila SI, Hellstrom PA, Kontturi MJ. Intrascrotal adenomatoid tumors and their ultrasound findings. *J Clin Ultrasound* 1993;21:33-7.
- (108) Hertzberg BS, Kliwer MA, Hertzberg MA, Distell BM. Epididymal leiomyoma: sonographic features. *J Ultrasound Med* 1996;15:797-9.
- (109) Stewart VR, Sriprasad S, Pomplun S, Walsh K, Sidhu PS. Sonographic Features of a Spermatic Cord Capillary Hemangioma. *J Ultrasound Med* 2007;26:139-42.
- (110) Choyke PL, Glen GM, Wagner JP, Lubensky IA, Thakore K, Zbar B, et al. Epididymal cystadenomas in von Hippel-Lindau disease. *Urology* 1997;49:926-31.
- (111) Sajjad SM, Azizi MR, Llamas L. Fibrous pseudotumor of testicular tunic. *Urology* 1982;19:86-8.
- (112) Wood A, Dewbury KC. Case report: paratesticular rhabdomyosarcoma - colour Doppler appearances. *Clin Radiol* 1995;50:130-1.
- (113) Stein A, Kaplun A, Sova Y, Zivan I, Laver B, Lurie M, et al. Leiomyosarcoma of the spermatic cord: report of two cases and review of the literature. *World J Urol* 1996;14:59-61.
- (114) Kuwabara H, Uda H, Sakamoto H, Sato A. Malignant mesothelioma of the tunica vaginalis testis. Report of a case and review of the literature. *Acta Pathol Jpn* 1991;41:857-63.
- (115) Backus ML, Mack LA, Middleton WD, King BF, Winter TC, True LD. Testicular microlithiasis: imaging appearances and pathologic correlation. *Radiology* 1994;192:781-5.
- (116) Amaechi I, Sidhu PS. Testicular microlithiasis and macrocalcification: prevalence of tumors and follow-up in a single center over 10 years. *Eur Radiol Suppl* 2008;18:175.
- (117) Miller FNAC, Sidhu PS. Does testicular microlithiasis matter? A review. *Clin Radiol* 2002;57:883-90.

- (118) Poulsen J, Sidhu PS, Holm M. Testicular microlithiasis - a sinister condition? In: Dawson C, Muir GH, editors. *The Evidence for Urology*. 1st ed. Shrewsbury: Tfm Publishing Ltd; 2005. p. 31-8.s
- (119) Woodward PJ, Sohaey R, O'Donoghue MJ, Green DE. Tumors and tumorlike lesions of the testis: radiologic-pathologic correlation. *Radiographics* 2002;22:189-216.
- (120) Ganem JP, Workman KR, Shaban SF. Testicular microlithiasis is associated with testicular pathology. *Urology* 1999;53:209-13.
- (121) Gilbert S, Nuttall MC, Sidhu PS, Ravi R. Metachronous Testicular Tumors Developing 5 and 9 Years After the Diagnosis of Testicular Microlithiasis. *J Ultrasound Med* 2007;26:981-4.
- (122) Bushby LH, Miller FNAC, Rosairo S, Clarke JL, Sidhu PS. Scrotal calcification: ultrasound appearances, distribution and aetiology. *Br J Radiol* 2002;75:283-8.
- (123) Miller FNAC, Rosairo S, Clarke JL, Sriprasad S, Muir GH, Sidhu PS. Testicular calcification and microlithiasis: association with primary intra-testicular malignancy in 3,477 patients. *Euro Radiol* 2006;17:363-9.
- (124) Martin B, Tubiana JM. Significance of scrotal calcification detected by sonography. *J Clin Ultrasound* 1988;16:545-52.
- (125) Gooding GA, Leonhardt WC, Marshall G, Seltzer MA, Presti JC. Cholesterol crystals in hydrocoeles; sonographic detection and possible significance. *AJR Am J Roentgenol* 1997;169:527-9.
- (126) Meacham RB, Townsend RR, Rademacher D, Drose JA. The incidence of varicoceles in the general population when evaluated by physical examination, gray scale sonography and color Doppler sonography. *J Urol* 1994;151:1535-8.
- (127) Dogra VS, Gottlieb RH, Oka M, Rubens DJ. Sonography of the Scrotum. *Radiology* 2003 ;227:18-36.
- (128) El-Saeity NS, Sidhu PS. "Scrotal varicocele, exclude a renal tumour". Is this evidence based? *Clin Radiol* 2006;61:593-9.
- (129) Mehta AL, Dogra VS. Intratesticular varicocele. *J Clin Ultrasound* 1998;26:49-51.
- (130) Das KM, Prasad K, Szmigielski W, Noorani N. Intratesticular varicocele: evaluation using conventional and Doppler sonography. *Am J Roentgenol* 1999;173:1079-83.
- (131) Browne RFJ, Geoghegan T, Torreggiani WC. Intratesticular varicocele. *Australas Radiol* 2005;49:333-4.
- (132) Dublin L, Amelar RD. Varicoele size and results of varicocelectomy in selected subfertile men with varicocele. *Fertil-Steril* 1970;21:606-9.
- (133) Gordon SJ, Otite U, Maheshkumar P, Cannon P, Nargund VH. The use of scrotal ultrasonography in male infertility. *BJU International* 2001;87:417.

- (134) Grainger AJ, Hide IG, Elliot ST. The ultrasound appearances of scrotal oedema. *Eur J Ultrasound* 1998;8:33-7.
- (135) Stewart VR, Sidhu PS. The testis: the unusual, the rare and the bizarre. *Clin Radiol* 2007;62:289-302.